




ELSEVIER

Contents lists available at ScienceDirect

Cancer Epidemiology

journal homepage: www.elsevier.com/locate/canep

A ten-year study of Retinoblastoma in Uganda: An approach to improving outcome with limited resources

K. Waddell^{a,b}, M. Matua^a, C. Bidwell^a, R. Atwine^b, J. Onyango^b, S.V. Picton^c, I. Simmons^c, J. Stahlschmidt^{c,d}, W.T. Johnston^{e,*}, R. Newton^e

^a Ruharo Eye Centre, Mbarara, Uganda

^b Mbarara University of Science and Technology, Mbarara, Uganda

^c Leeds Teaching Hospitals NHS Trust, Leeds, United Kingdom

^d Jack Birch Unit for Molecular Carcinogenesis, Department of Biology, University of York, United Kingdom

^e Epidemiology and Cancer Statistics Group, Department of Health Sciences, University of York, York, United Kingdom

ARTICLE INFO

Keywords:

Retinoblastoma
Survival
Limited resources
Chemoreduction
Vision conserved
Late presentation

ABSTRACT

Background: Survival of children with cancer in resource-limited regions is very poor compared to better-resourced regions. Retinoblastoma (RB) is a childhood cancer that is commonly reported in many regions of Africa. RB may be safely and effectively treated by non-specialists, which could facilitate more widespread availability of treatment in under-resourced areas.

Methods: A ten-year consecutive series of children with RB treated at Ruharo Eye Centre between December 2009 and November 2019 was prospectively followed up. Chemoreduction followed by surgery is the standard approach to therapy. Costs of therapy and also of travel and food are borne by the program which is unaffordable to most families and necessitates donors. Survival by stage of RB and number of eyes affected was described using Kaplan-Meier plots. Visual acuity was assessed for all children with bilateral disease and the retention of sight during follow-up assessed.

Results: Among 665 children with RB, 18.2 % (121 children) presented with metastatic (Stage 4) RB with only two of these children surviving >24 months. Five-year survival was 60.2 % among all children with RB rising to 93.3 % and 87.2 % for children with unilateral and bilateral Stage 1 disease, respectively. Among 184 children with bilateral disease, 130 (70.7 %) retained some level of sight following primary treatment with 91 of those (49.5 % of all bilateral children) retaining vision up to their death or to the end of follow-up.

Conclusion: Many children in Uganda present with advanced RB and curative treatment is not possible in this setting. Children diagnosed and treated early have good prospects of survival. Retention of sight among many bilaterally affected children is achievable, facilitating access to normal education. Therefore, the strategic priorities for improving survival are changing community perceptions so that children with eye problems are brought without delay, and widening access to modern treatment by using general health workers with standard drugs, backed by financial, social and peer support.

1. Introduction

A recent review of global childhood cancer burden finds that data from low- and middle-income countries are scarce although 90 % of children with cancer reside there. It goes on to suggest that survival is substantially worse than in high income countries [1]. Retinoblastoma (RB) is one of the most commonly reported childhood cancers in Africa, and was said to be the commonest eye cancer overall until overtaken in sub-Saharan Africa by HIV-associated conjunctival carcinoma [2]. In

East Africa, access to treatment for RB is sparse with only a few university departments offering modern treatment while some neighbouring countries have no provision. Our nation-wide study in Uganda between 2006 and 2009 documented 3-year survival of only 45 % among children treated at Ruharo Eye Centre when only enucleation with occasional radiotherapy (cobalt 60) were available [3]. This contrasts with near 100 % survival in countries with adequate resources [4–6]. Our further study (2006–2013) showed a 37 % reduction in the risk of dying from RB in Uganda following the introduction of

* Corresponding author. Present address: Epidemiology and Cancer Statistics Group, Department of Health Sciences, University of York, Heslington, York, YO10 5DD, United Kingdom.

E-mail address: tom.johnston@york.ac.uk (W.T. Johnston).

<https://doi.org/10.1016/j.canep.2020.101777>

Received 30 March 2020; Received in revised form 26 June 2020; Accepted 29 June 2020

1877-7821/ © 2020 Elsevier Ltd. All rights reserved.

chemoreduction using standard chemotherapy at Ruharo Eye Centre late in 2009 [7]. We also showed that non-specialists could safely administer the treatment potentially making it much more widely available. A cost-benefit analysis was favourable in terms of life years saved and blind years prevented. However, the expense of this treatment is beyond most families and full financial support including transport and food was essential for preventing abandonment of treatment.

This treatment approach has continued as routine since 2013, and the current report documents outcome for all children intended to be treated with chemotherapy since 2009. A large number of children are included with a high rate of treatment completion and follow up. For children with heritable bilateral disease who risk loss of both eyes, levels of sight conserved or lost over the course of the treatment is traced. Despite improved survival, the major cause of death remains late presentation highlighting the importance of palliative management of incurable RB. The numbers of new patients have increased markedly and the program now includes second line agents if standard treatment fails, intravitreal chemotherapy, intensified use of local modalities (laser and cryotherapy) and improved prosthetics after enucleation. Clinical details of these are presented here only in brief (see Supplement for further details), and emphasis will be on reproducible strategies for success in under-resourced regions.

The context of this report is recognition that for much of sub-Saharan Africa more advanced investigations and treatments like routine cranial scans, intra-arterial chemotherapy, conformal radiotherapy, granulocyte-colony stimulating factor and retinal photography are not yet available or are unaffordable. However, despite this, major improvement in outcome is achievable now and is long overdue. Moreover, since late presentation accounts for most mortality, the largest improvement by far would result not from the introduction of expensive advanced technology but from changes in community perceptions. Communities need to understand that curative treatment is available and, at Ruharo Eye Centre, financially supported. Health care workers need to consider RB and facilitate early referral to appropriate centres. With successful outcomes, the stigma and fear of facial deformity after enucleation will be avoided by good prosthetics. Thus, the priorities are community education and the wide availability of effective referral centres with financial and family support.

2. Materials and methods

This is a prospective, observational study of a consecutive series of children presenting at Ruharo Eye Centre, Uganda, between December 2009 and November 2019 with a final diagnosis of RB. All children were intended to be treated with standard chemotherapy as the initial intervention (chemoreduction). Enrolment, information and consent, record keeping and chemotherapy (vincristine, etoposide and carboplatin using peripheral veins) are as in previous papers [3,7]. Fuller details of clinical management are available in the Supplement.

Staging of RB on enrolment to this study was based upon the International Retinoblastoma Staging System (IRSS) [8]. This system divides the entire intra- and extra-ocular spectrum into four stages. Stage 1 is complete resection of intraocular tumour or its ablation by chemotherapy, expecting 100 % survival. Stage 2 is microscopic residual tumour (also termed minimal metastatic dissemination) with good but not total survival. Stage 3 is macroscopic extension to orbit or local lymph nodes, further lowering survival. Stage 4 is metastatic disease (usually intracranial or bone marrow) with minimal survival expected. However, the system as published presumes full resources and is brief, so more detailed criteria suitable for resource-limited regions were selected from published systems using both clinical and pathological features and used for this study (Box 1) [9–12].

In earlier years, full histology was sometimes unavailable but is now obtained from Mbarara University Pathology Department, with additional review carried out in Leeds, UK. After fixation of the enucleated eye for 48 h the resection margin of the optic nerve is marked with

Indian Ink and the proximal portion removed for separate processing. The initial gross cut of the eye into two halves is then done by the surgeon to provide immediate clinical information and for photographic records before being sent for detailed histology. Recording of results includes the clinical and pathological TNM (Tumour, Node, Metastasis) system to aid staging (Box 1 [9]).

Follow up is on-going and was intensified starting in the last six months of the study, aiming to update outcomes for every child as recently as possible. Follow-up is counted as complete if, in this period or onwards, the child has been seen in clinic or at home visit, or family contacted by telephone. For those whose follow up was already four years or more it was counted complete if contacted in the final year of the study. For non-survivors, follow-up was to death, with a few inaccessible terminal children presumed died and date estimated.

Survival is reported with Kaplan-Meier estimates stratified by stage and by involvement of one or both eyes. Vision in children with bilateral disease but having at least one conserved eye was assessed by formal testing of visual acuity appropriate for age, or estimated from fundal appearance. To predict educational needs, final central vision was divided into 4 broad categories: normal central vision (6/18 or better, macula uninvolved), moderate impairment (tumour or scar encroaching on macula, fovea spared), major impairment (macula ablated) and blind (usually enucleation). Data were collected and held using Epi Info (Version 7.2; Centers for Disease Control, USA) [13] and all analyses were undertaken using SAS software (Version 9.4, The SAS Institute, Cary, NC, USA) [14].

3. Results

In 10 years, 665 children with RB were enrolled; annual enrolments increased over this period with children travelling from across Uganda and from neighbouring countries to access RB treatment at Ruharo (Fig. 1). Overall, 26% of children had bilateral disease, there was a small male majority and the median age at diagnosis was 29 months (Table 1, Fig. 2). Nearly all children completed follow-up (range 1 day to 128.4 months) and there was a low level on non-compliance (Table 1). There were 23 children (18 bilateral, 5 still unilateral) from 12 families having siblings or parents with RB, all others reporting no family history. Five children tested positive for Human Immunodeficiency Virus on admission, of whom three were on anti-retroviral therapy and two reverted to negative having maternal antibodies. One of these three had metastatic disease and died. The others tolerated chemotherapy uneventfully and are well. Seven children died within 4 weeks after chemotherapy when leucopaenia could have been responsible. They were at home so details of the cause of death are uncertain but two were advanced cases for palliation only. For context, in the 5 years 2014–2018 there were 1968 chemotherapy courses given.

To illustrate the annual workload of the program, in the calendar year 2018 there were 768 admissions for the 105 newly presenting children and those of previous years still under treatment or monitoring. There were 460 courses of chemotherapy, 99 enucleations, 106 local treatments (laser and cryotherapy) and 31 intravitreal injections. For these procedures, and for monitoring progress, 390 general anaesthetics were given. There were no significant complications; 4 children had mild reactions to carboplatin which was permanently discontinued. In addition, 7 children with other ocular or orbital malignancies who had been referred on suspicion of RB were treated in collaboration with the Children's Cancer Unit at Mbarara Regional Referral Hospital.

After stratifying the children by the modified IRSS criteria (Box 1), Fig. 3 shows their distribution and Fig. 4 presents their survival as Kaplan-Meier curves, separately for unilateral and bilateral disease. Children who received no treatment because parents or carers declined, or if treatment considered vital for survival was interrupted for more than 6 months, are presented separately so as not to obscure what is currently achievable. Overall five-year survival was 60.2 %. Stage of disease was a strong determinant of survival: Five-year survival in Stage

Box 1

Modified International Retinoblastoma Staging System (IRSS) used in this study, adapted from Chantada et al. 2006, Amin et al. 2017, Shields et al. 2006 and Linn Murphree et al, 2005.

Stage 1	Totally intraocular, with/without local invasion	Clinical	cT1	ICRB group A/B intraretinal tumours sub-retinal fluid = < 5mm from base ICRB group C/D, subretinal/vitreous seeds, subretinal fluid = >5mm from base No choroid or pre- / intralaminar invasion, no anterior segment invasion a. Focal choroid, pre / intralaminar invasion b. Invasion of stroma of iris, trabeculum or Schlemm's canal
			cT2	
Pathology	pT1			
	pT2			
Stage 2	Microscopic residual tumour	Clinical	cT3	a. Pre- / phthisis b. Ciliary body, lens, anterior chamber invasion c. Raised intraocular pressure, neovascular glaucoma, buphthalmos d. Hyphaema, vitreous haemorrhage e. Aseptic orbital cellulitis a. Choroid invasion massive >3mm / full width b. Postlaminar nerve invasion not margin c. Inner 2/3 scleral invasion d. Full thickness sclera
Pathology	pT3			
Stage 3	Macroscopic regional extension	Clinical	cT4	Ultrasonic invasion of orbit or optic nerve, moderate proptosis / orbital mass or recurrence Regional lymph node involvement Limited transcleral invasion of orbit, fat, muscle, conjunctiva, nerve margin free or minimal Lymph node involvement, pre-auricular or cervical
			cN1	
Pathology	pT4			
	pN1			
Stage 4	Metastasis	Clinical	cT4	Haematogenous: skull tumour, paraplegia; CNS: visible nerve resection margin involvement, massive orbital or adnexal tumour Distant metastasis without microscopic confirmation Major optic nerve involvement at resection margin indicating CNS involvement Distant metastasis at any site with microscopic confirmation
			cM1	
Pathology	pT4			
	pM1a			

1 was 87.8 %, decreasing to 73.0 % in Stage 2, 21.6 % of children in Stage 3 survived 5 years and only two children with Stage 4 disease have survived 2 years. Survival among the 34 children whose treatment was declined or interrupted was comparable overall to those with Stage 3 disease. Although curves for unilateral and bilateral differ, the p-values comparing them were non-significant at any stage.

For the 184 children with bilateral disease who are therefore at risk of blindness (omitting 5 currently with unilateral disease but with siblings or parents with RB so are presumed to have heritable disease), 71 (38.6 %) were assessed as having full vision at the time of enrolment whilst 48 (26.1 %) were assessed as blind. At the end of their primary treatment 8 children had lower vision than prior to treatment however 23 children showed immediate improvement in visual acuity (Table 2). Among the 130 bilateral children with some vision after primary treatment, 91 (70.0 %) retained some vision to their death or to the end of follow-up (Fig. 5); 35 (26.9 %) had enucleation after the end of primary treatment. Children with severe visual impairment at the end of primary treatment were the least likely to retain vision throughout follow-up: no child has retained vision beyond 30 months as yet (Fig. 5). Overall, 60.5 % of currently surviving children with bilateral disease retain some vision, with 49.6 % retaining full central vision. Currently the affected eyes of 10 unilateral children are conserved as are both of 6 children with bilateral disease, the remainder have had enucleation or are expected to need it.

4. Discussion

Eye workers in Africa are sadly familiar with receiving distressed children having advanced, fungating, incurable tumours. The wide gap in survival between world regions is well documented to be dependent on resources. With the large childhood populations in regions such as Africa, most of the world tally of deaths occur there [2,15]. In this 'majority world' it is time to stop accepting this as unchangeable. Modern treatment needs urgently to become much more widely available now and not wait for the arrival of a fully resourced university nearby. Although RB management should be restricted to referral centres with the necessary expertise, equipment and funding, the issue

is whether non-specialists in general eye units can develop the necessary skills so as to expand availability. Cancer is usually managed by a multidisciplinary team led by oncologists, with the surgeon responsible only for the biopsy or excision, but at present oncologists are few in Africa. Retinoblastoma is exceptional in requiring the surgeon (the ophthalmologist) to be responsible not only for the one-off enucleation but also for frequent intraocular examinations and treatments. Because of this and the relatively low toxicity of the chemotherapy, ophthalmologists are in a position to lead the team and make the management decisions. This study confirms that safe, effective treatment is possible in this way which may help to rectify the lack of treatment accessibility identified in the global studies [1,15]. This study also shows that the frequent abandonment of treatment often reported is not inevitable, and that near total follow up is achievable in the age of mobile telephones [16].

If we consider a schematic pathway to treatment (Fig. 6), presentation at a known RB centre (Ruharo for example) is the starting point for children to access the types of effective treatment detailed here. It is not known how many children develop RB in Uganda nor is it known what proportion of affected children are presented for diagnosis and eventual treatment. Regrettably, this study again highlights the problem of delayed presentation, allowing only palliation for many children (Stage 4 in Fig. 4). Delay is understandable for parents with large families living by subsistence far away from treatment centres who do not perceive urgency for something painless in one child's eye. However, even more affluent parents not from afar may also delay, not perceiving the value of accessing services. Some have ideological reasons for delaying, or for declining, free treatment even when they do come. Programs to influence public understanding are now running, and change in socio-cultural attitudes must be the prime target for reducing the rate of death due to RB. This can only come about when the community has learnt that effective, financially supported treatment is now available, and when healthcare workers facilitate rapid referral. The rising numbers of children presenting at Ruharo show that community awareness has grown and possibly that a greater proportion of affected children are receiving treatment. Currently this is also resulting in a rise in the number of children for whom only palliation is possible,

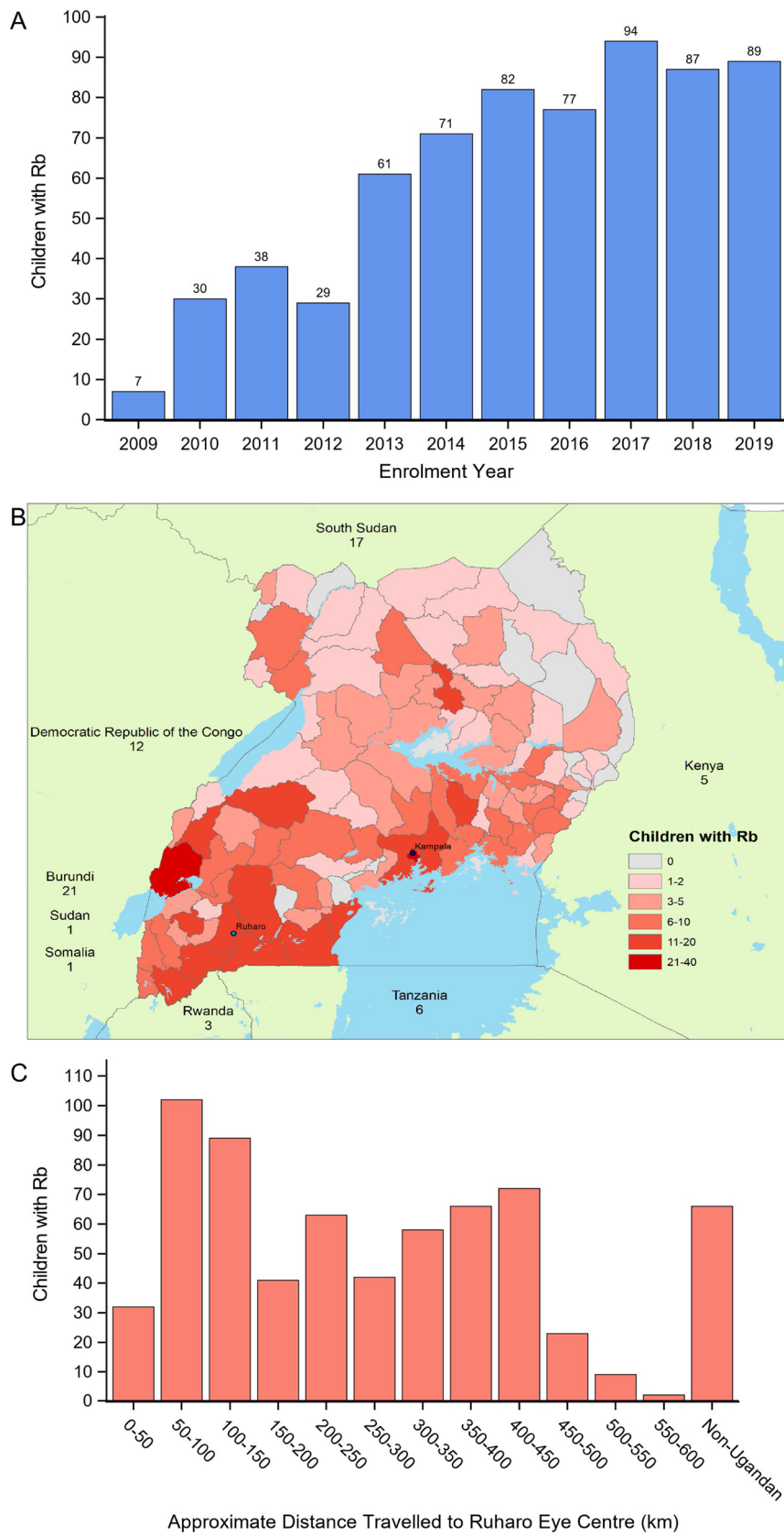


Fig. 1. Children with RB seen at Ruharo Eye Centre and enrolled into this study between Nov 2009 and Nov 2019 by year (A), home district or country (B) and by approximate distance travelled to Ruharo (C). 2009 represents 1.5 months of enrolment and 2019 represents 11 months of enrolment. For a colour version of the map, the reader is referred to the web version of this article.

Table 1

Children with RB enrolled at Ruharo Eye Centre 15 Nov 2009 – 30 Nov 2019 showing number by laterality, sex, nationality and completeness of follow-up and the median age at enrolment. The number of children receiving interrupted or delayed treatment is also shown.

Laterality	N	Males (%)	Females (%)	% aged 0–5 yr	Ugandans (%)	Complete follow-up (%)	Non-compliant or >6 month delay (%)
Total	665	355 (53.4)	310 (46.6)	89.5	599 (90.1)	94.4	41 (6.2)
Unilateral	481	260 (54.1)	221 (45.9)	86.5	435 (90.4)	93.6	17 (3.5)
Bilateral	184	95 (51.6)	89 (48.4)	97.3	164 (89.1)	96.7	24 (13)

Follow-up is as defined in the text.

but in the interim, this is valuable for compassionate reasons and will hopefully be temporary.

There is an unresolved question as to which is better, initial chemoreduction for all, or immediate enucleation followed by selective chemotherapy. Most eyes, even if the tumour is still intraocular, are at enrolment already Group E in the International Classification of RB (ICRB), as shown by the small number of conserved first eyes. This is the most advanced group with no prospect of saveable sight and with a tumour too large for likely cure by chemotherapy alone. Enucleation therefore is vital and avoiding refusal is life-saving [16]. This study confirms our previous experience that refusal is markedly reduced (but not totally eliminated) by starting with chemoreduction. This allows peer support by parents of children already satisfactorily treated. When the parents are initially in a state of emotional shock on being told the diagnosis, our counseling focusses on the response to chemotherapy, delaying discussion of surgery until it becomes indicated. The exceptions are when pain and distress necessitate immediate surgery (which in this situation is readily accepted), or if the issue is raised by the parents. In the African cultural environment this benefit alone justifies chemoreduction as the norm. It is also reasonable medically in the setting of relatively advanced disease where minimal metastatic dissemination may be already occurring despite the tumour appearing still

intraocular, as shown by the reduced survival in Stage 2. A recent study in Central America has reported favourably on chemoreduction [17]. The concern that it obscures need for further chemotherapy appears unfounded as does the assertion that initial chemotherapy increases mortality [18]. However, chemoreduction for all children does have major drawbacks; it is labour-intensive and expensive and it carries a risk of serious sepsis from leucopaenia although the frequency in this study is very low. It also does not permit hindsight; an unknown proportion of children might have been cured with surgery alone. There are also cases where no tumour is subsequently found on histology however, this does not rule out the diagnosis, notably in advanced phthisis following sterile panophthalmitis or when the tissue on the slides is fragmented. Initial chemotherapy also relies on accurate differential diagnosis which can be equivocal even in experienced hands, notably with atypical exudative retinopathy, so some without cancer may be treated. Against these drawbacks has to be set the reduction of the high mortality from refusal of enucleation and abandonment of treatment by giving parents time to understand the condition. There are no comparable published studies in this setting where immediate enucleation with selective chemotherapy is standard so the question which is better remains unresolved for lack of evidence.

The correct technique of enucleation is important, because if the

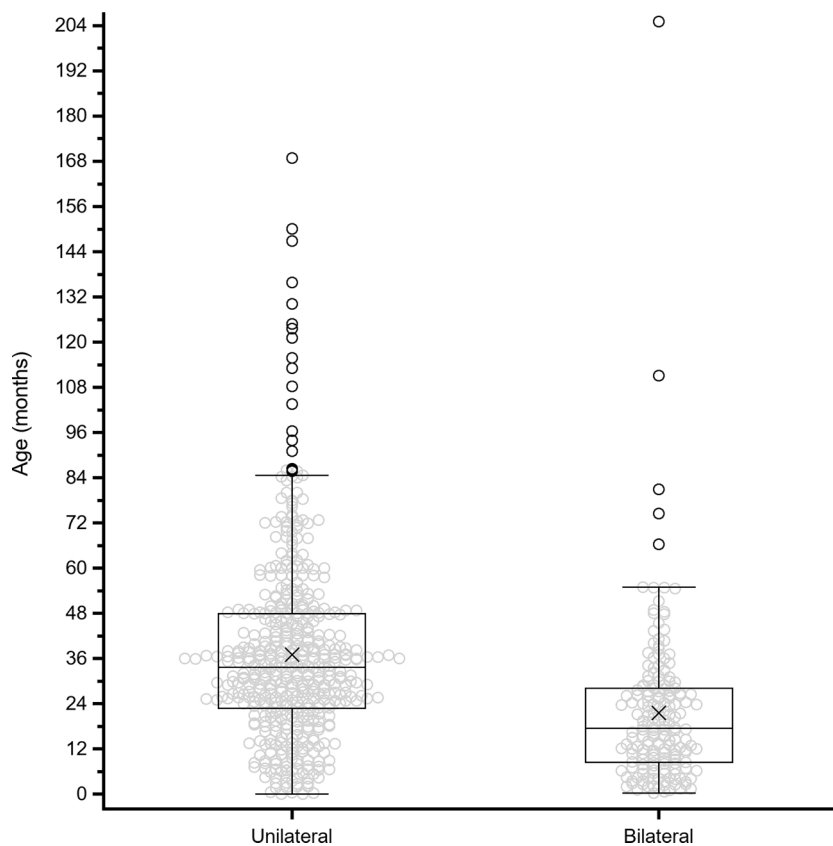


Fig. 2. Age at diagnosis (months) for children admitted to Ruharo Eye Centre between Nov 2009 and Nov 2019 with unilateral or bilateral disease. The x denotes mean age.

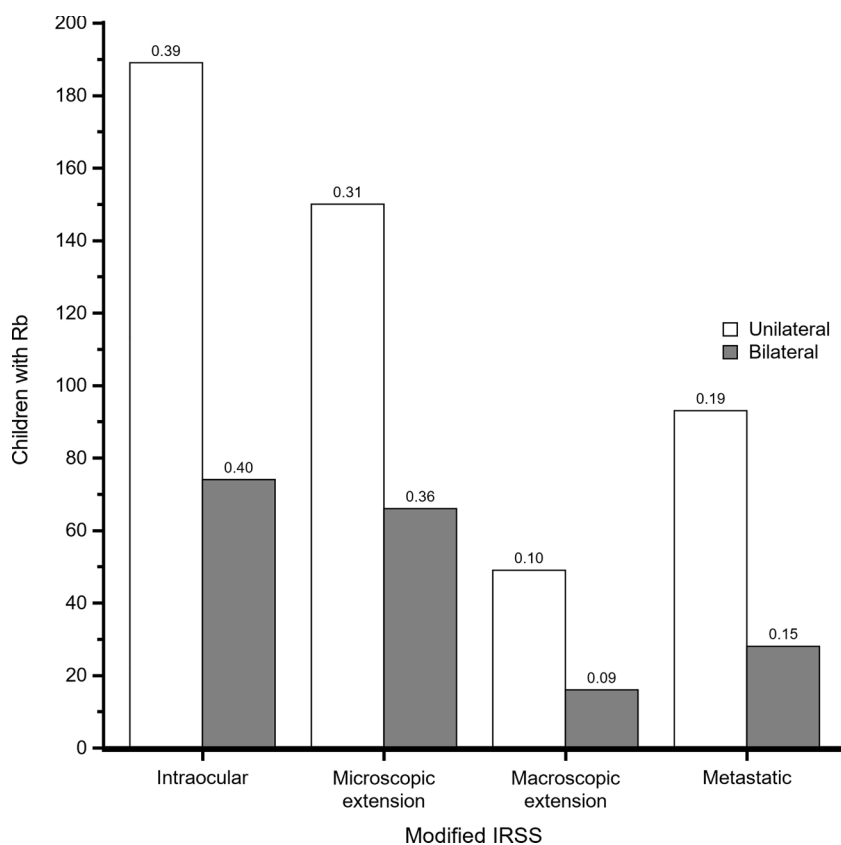


Fig. 3. Distribution of children with RB by number of eyes affected and stage of disease in the most severely affected eye. Bars are labelled with the proportion of children in each stage by laterality. ICRB groups A–D are represented among Intraocular children (although most were groups C and D) whereas all other children were ICRB group E.

tumour has extended into the optic nerve, it is life-saving to section the nerve at the orbital apex beyond the extension and so training is important. Facial appearance must also be considered because fear of facial disfigurement is a disincentive to accepting enucleation. Children with an empty socket have a hard time at school and may refuse to attend, so myoconjunctival attachment of the muscles to give mobility of the prosthesis and an orbital implant are essential (details are in the Supplement). We are currently gaining experience with dermofat grafts from the buttock used secondarily for contracted sunken sockets. They could also be beneficial as primary implants especially among those under 4 years of age when the socket is still growing, but they add to surgical and healing time. Stock prostheses obtained from India look acceptable for most African children, and we are now setting up to make custom-designed ones.

With massive orbital extension or visible optic nerve involvement to the resection margin, metastasis has already occurred and only palliation is possible. Debulking by chemotherapy without surgery is possible but this may consume the child's last months of life. Formal exenteration of the orbit is not life-saving at this point. Therefore, our program uses immediate extended enucleation giving rapid relief and a return to normal life. The terminal event is usually a rapid deterioration over minutes or hours with features of raised intracranial pressure or haemorrhage. Infrequently there is slow decline over several weeks and only rarely skull metastases or paraplegia, but offensive orbital recurrence has nearly disappeared. Good palliation for the final months is usually achieved and is appreciated by the parents.

The curves of Fig. 4, as expected, show decreasing survival with more advanced disease, and the precipitous fall in survival when the tumour becomes extraocular at Stage 3. It also shows the risk of declining treatment - some survive but with uncertain future. It is disappointing that there is still not total survival in Stage 1 when the tumour is fully intraocular and chemotherapy has been given, though the great majority do survive. In Stage 2 better survival might also be expected, because even though there may be minimal metastatic spread

this should be eradicated by chemotherapy. A few deaths may be from chemotherapy toxicity. Three bilateral children in remission have died from osteogenic sarcoma, illustrating the on-going cancer risk that children with a germline mutation face. Some unexpected deaths may be from incorrect staging since information for criteria may be incomplete. The criteria chosen for staging are provisional and still to be validated. Validation will be complicated because the various systems of classification do not harmonise closely [9–12]. Information from the families suggests deaths in children with good prognosis and in remission is usually from intercurrent infections or malaria, with social dysfunction added. Uganda still has a substantial under-5 mortality; the most recent estimate being 64 deaths per 1000 live births (6.4%) [19]. When the tumour becomes extraocular (Stage 3) as yet few survive but this could be changed when modern radiotherapy becomes more widely available. Stage 4 as judged from massive orbital tumour or visible nerve resection margin involvement signaling metastasis is incurable in this setting. This has been shown also in India even when advanced imaging and radiotherapy are available and justifies the decision for palliation alone in Stage 4 disease [20]. Second line chemotherapeutic protocols are available if the standard agents fail but as yet are of uncertain efficacy. In contrast, the extended action of intravitreal therapy for subretinal as well as vitreal seeding and even retinal tumours holds promise of improving both survival and conservation of vision [21]. For this we have changed from using melphalan because of toxicity and now use topotecan with apparent equal success [22].

Children with bilateral disease face blindness if bilateral enucleation is necessary to save life. This is a common situation, as they may have advanced bilateral disease at enrolment even if young infants and they may continue to produce new tumours since they have a germline mutation. Parents understandably find it very difficult to accept second enucleation when there is still a glimmer of sight and so may delay until too late. Testing acuity in young children is difficult, so many are estimated from fundal appearance. The four broad grades we have used broadly predict educational requirements: Grade 1 children with full

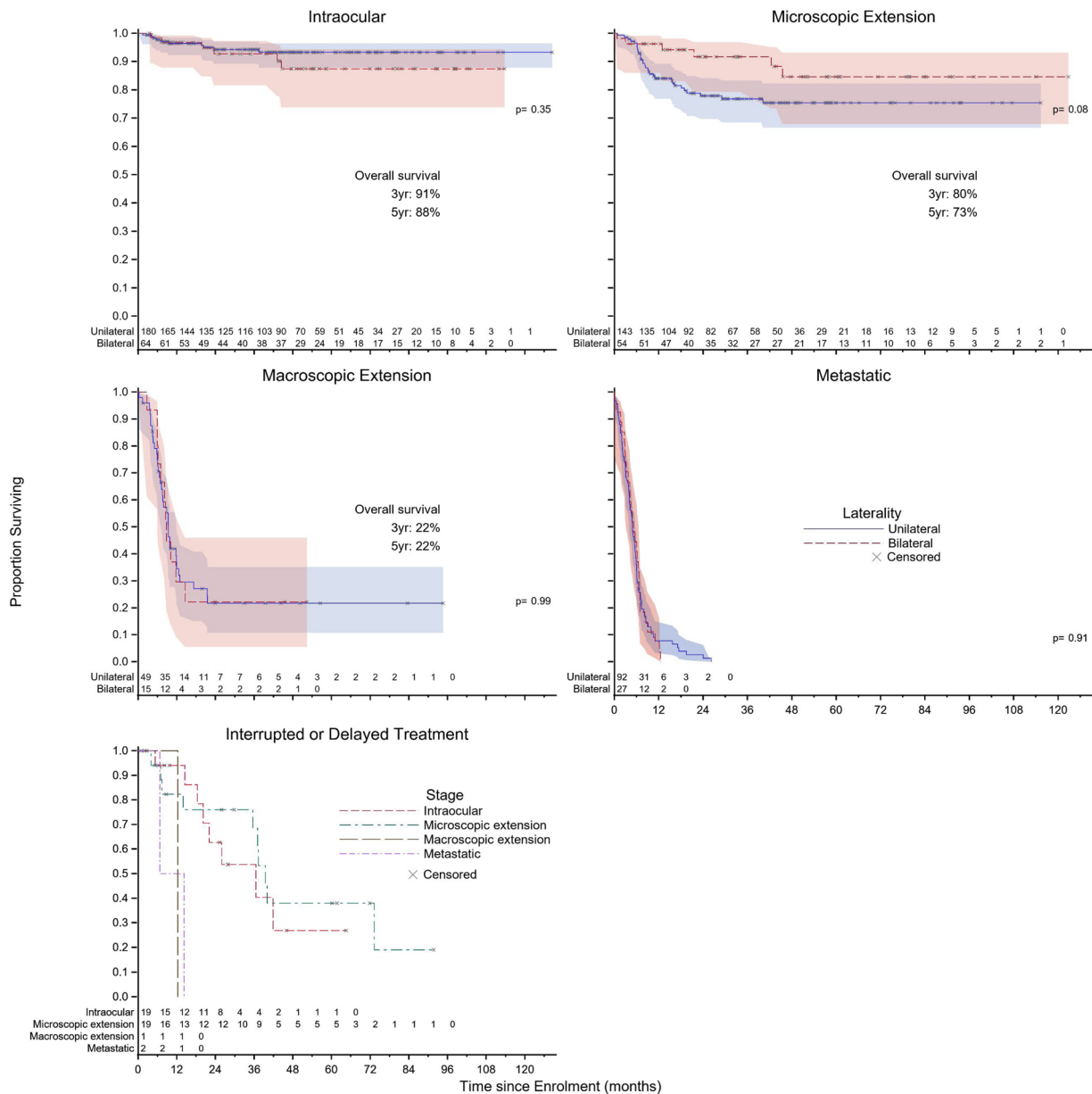


Fig. 4. Survival of children with RB. Kaplan-Meier estimates grouped by modified IRSS stage and stratified by number of eyes affected. Staging based on most severely affected eye in children with bilateral disease. Children whose start of treatment was delayed or later interrupted by at least six months are presented separately. P-values indicate result of a log-rank test comparing the survival of children with unilateral and bilateral disease within each stage. Shaded areas indicate 95 % point-wise confidence limits. For a colour version of this figure, the reader is referred to the web version of this article.

central vision but variable peripheral impairment can access normal education, grade 2 (moderate impairment) children can use print education with low vision devices if necessary, grade 3 (major impairment) children can mostly use non-visual media (computer or

Braille), and grade 4 (blind) children will require entirely non-visual media. Table 2 shows that vision can improve between enrolment and end of primary treatment with chemotherapy, and that those with normal vision usually retain it. Fig. 5 traces the period of retention of

Table 2
Vision assessments for bilateral children at time of enrolment and at the end of primary treatment[†].

Vision at enrolment		Vision after primary treatment						
	n	Full Vision		Moderate Impairment		Severe Impairment		Blind
Full Vision	71	71	(100.0)	0	(0.0)	0	(0.0)	0 (0.0)
Moderate Impairment	19	5	(26.3)	13	(68.4)	1	(5.3)	0 (0.0)
Severe Impairment	46	7	(15.2)	10	(21.7)	22	(47.8)	7 (15.2)
Blind	48	0	(0.0)	0	(0.0)	1	(2.1)	47 (97.9)
Total	184	83	(45.1)	23	(12.5)	24	(13.0)	54 (29.3)

[†] Primary treatment ending defined as the end of the initial chemotherapy courses (ranged from 1 to 6 courses) with one calendar month for each course.

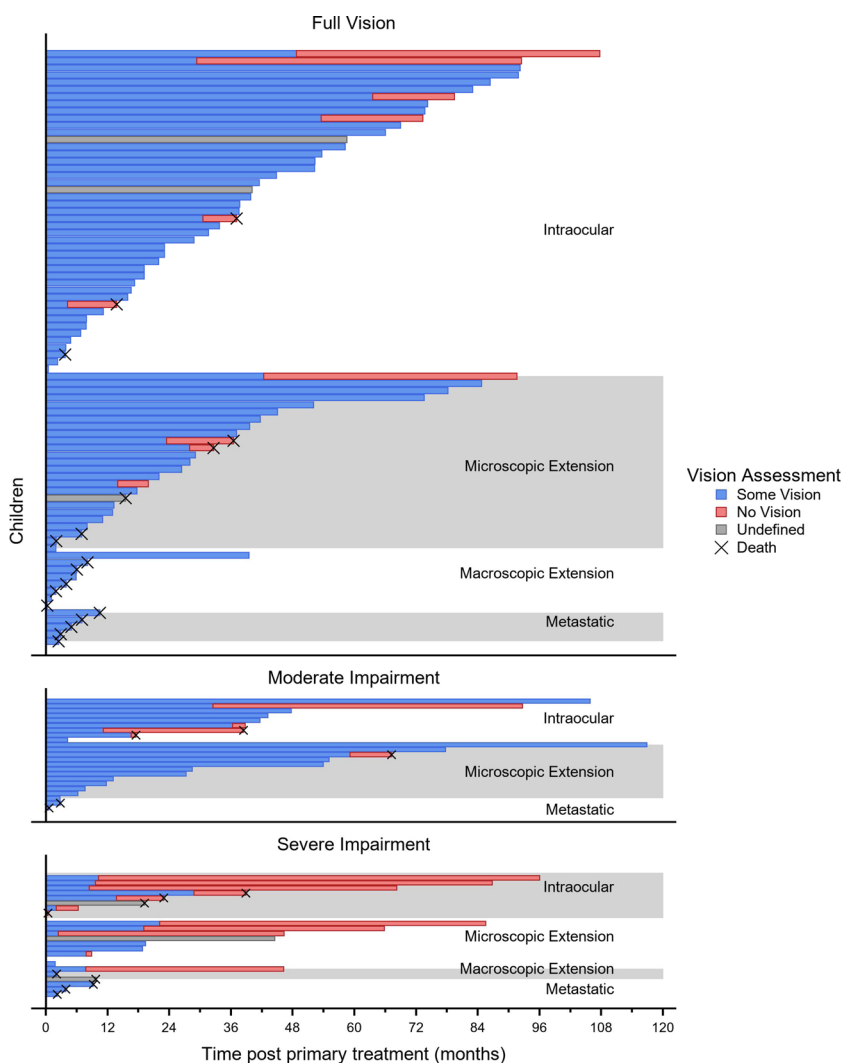


Fig. 5. Time vision was retained post-primary-treatment for children with bilateral disease stratified by visual assessment at end of primary treatment and stage of disease. Stage of disease based on most-severely affected eye; children blind after primary treatment have been excluded. Blue bars indicate time with at least some vision retained; red bars denote time when child was blind. Gray bars indicate children who retained some vision after primary treatment and were blind at last contact but the time when the child transitioned from having some sight to having no sight could not be determined. (For interpretation of the references to colour in this figure legend, the reader is referred to the web version of this article).

vision after primary treatment stratified by grade at that point. Even if sight is ultimately lost, conservation for a period may be beneficial for the child's development. Most surviving bilateral children have either normal vision (49.5% of survivors) or are blind (39.5%), with only few in intermediate grades. Amongst these survivors, just over half retained full central vision, but over a third were blind and will need special education, which must be considered by financial sponsors.

Previously, complete histology was available only intermittently affecting the accuracy of staging however improved histology is now available. Overcoming the technical difficulty of sectioning eyes with their tough sclera but soft contents remains a challenge although improvements are being made. Accurate histology to identify high risk features is especially important if treating RB with initial enucleation alongside chemotherapy selecting children according to risk. The absence of accurate histology is another indication for routine chemoreduction. It is instructive for surgeons themselves to examine and measure specimens carefully at time of surgery, and to make the preliminary grossing cut after fixation and inking the optic nerve resection margin to assess the tumour. Categorising histopathological findings in a TNM format is essential [9,12]. Further understanding is gained if the pathologist and the clinician review the pathological and clinical findings together to decide on a therapeutic approach.

The workload for such a program is ever increasing. Expertise can be gained by staff spending time with an already established program. There should ideally be a dedicated ward and an uninterrupted supply of medicines. Surgery with good anaesthesia must be available

(ketamine is safe and convenient), as must cryotherapy and a diode laser with head-mounted delivery. Children with bilateral tumours, although a minority, make a heavy contribution to workload because interventions to conserve the second eye to avoid blindness may take years of multiple admissions and may even then fail. Another heavy contribution to workload is the need to repeatedly examine children whose primary treatment is completed successfully so as to identify recurrent or new tumours which could be ablated whilst still small. This applies especially to bilateral (heritable) children where new tumours can develop over several years, usually up to about 7 years of age but as late as 17 years old as seen in this study. Siblings should also be examined especially if there is a family history or bilaterality. The follow-up schedules recommended in high income countries are unrealistic and have to be modified for programs with many children [21]. This workload could be reduced if genetic information was obtained, to concentrate follow up on those with a germline mutation. Currently this is not easy to access and in the African cultural environment great care must be taken not to increase blame which may already exist within the family.

The overall conclusion is that at the present time it is possible to establish more treatment centres in under-served parts of sub-Saharan Africa; we have assisted this in Rwanda and Burundi. In Uganda, the Eye Department of Mulago Hospital along with the Uganda Cancer Institute in the capital city, Kampala, are developing their program. Further dispersed centres using non-specialists are needed but the obstacles are getting sufficient staff to undertake the heavy workload and

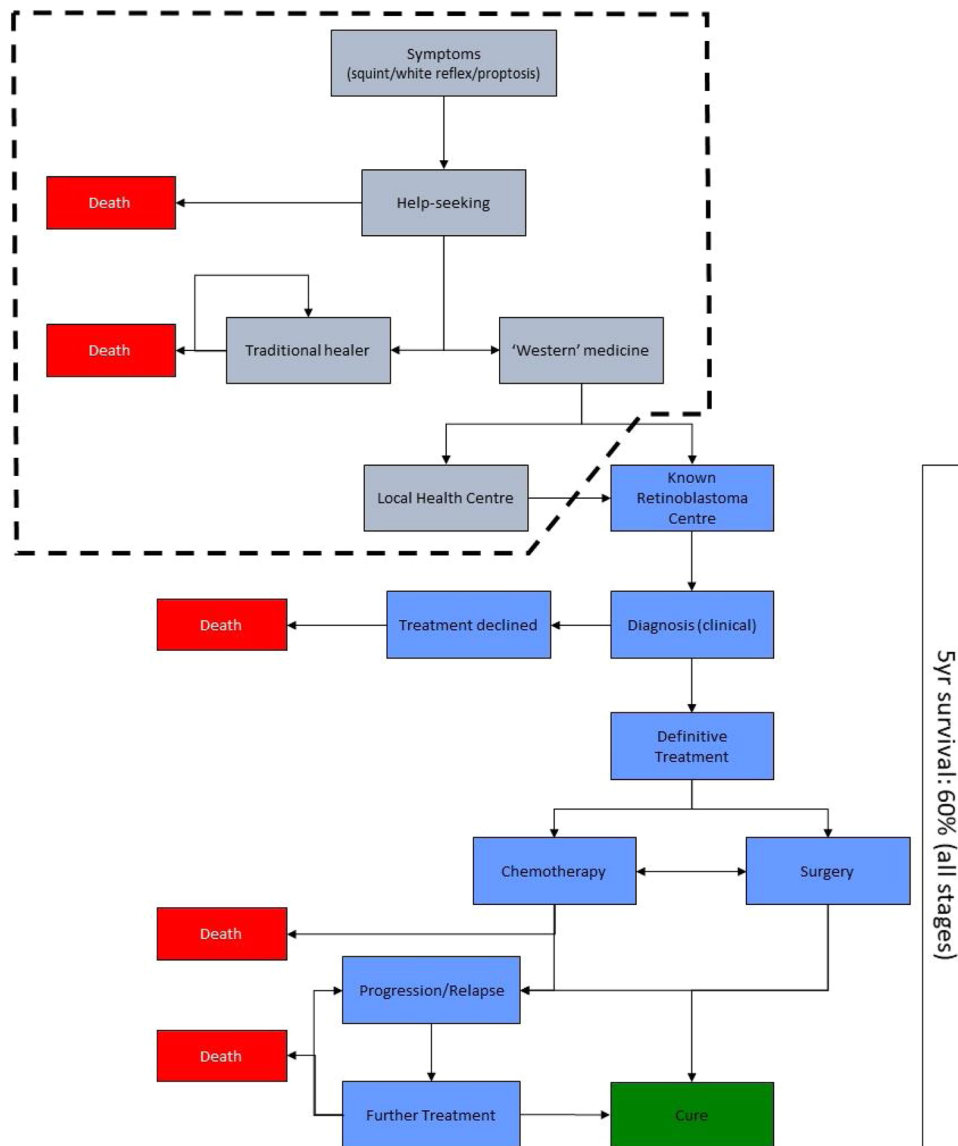


Fig. 6. Schematic pathway to treatment of children with RB in Uganda. Blue boxes represent stages of the pathway that occur after presentation at Ruharo Eye Centre (a known RB centre). Boxes enclosed in the dotted lines occur prior to presentation and represent an unknown number of children with RB. Mortality among children with RB prior to presentation at a known RB centre is not known. (For interpretation of the references to colour in this figure legend, the reader is referred to the web version of this article).

securing adequate funding which must include social costs like food and transport, not just treatment. Our program had been budgeted since the start at €1000 per newly diagnosed child, but with rising costs €1400 is now necessary. This sounds too costly in Africa but our previous cost/benefit analysis was favourable and we are now planning a larger in-depth analysis [7]. It must be emphasised that success depends on adopting strategies adapted to resource limited regions. These include using trained, but non-specialist, nursing staff supervised by senior, but generalist, clinicians, and affordable off-patent drugs. It encompasses a holistic approach with sensitive counselling, treatment in groups allowing peer support from other families, adequate financial support and children returning home between treatments so parents can care for the whole family. With the current global emphasis on addressing non-communicable disease, the time is ripe for these developments.

Authorship contributions

KW: Design, treatment of children, collating data, analysis, staging

system, writing of paper.

MM: Lead for treatment of children.

CB: Lead for chemotherapy, follow-up.

RA: Histopathology.

JO: Management of children, ethical approval.

SVP: Design of study, program advisor for chemotherapy.

IS: Design of study, program advisor for surgery.

JS: Design of study, program advisor for histopathology.

WTJ: Statistical analysis, writing of paper.

RN: Funding, design, conduct, analysis of study, writing of paper.

Authors read, commented and approved the final version of the manuscript.

Ethical approval

The study which launched the program in 2006 and the addition in 2009 for starting chemotherapy was approved by the Ethics Committee of Mbarara University of Science and Technology (Ruharo Eye Centre is affiliated) and by the Uganda National Council for Science and

Technology. The program has since used the original protocols for clinical management and data collection.

CRedit authorship contribution statement

K. Waddell: Conceptualization, Methodology, Investigation, Data curation, Writing - original draft, Supervision. **M. Matua:** Investigation, Writing - review & editing. **C. Bidwell:** Investigation, Writing - review & editing. **R. Atwine:** Investigation, Writing - review & editing. **J. Onyango:** Investigation, Project administration, Writing - review & editing. **S.V. Picton:** Conceptualization, Methodology, Supervision, Writing - review & editing. **I. Simmons:** Conceptualization, Methodology, Supervision, Writing - review & editing. **J. Stahlschmidt:** Conceptualization, Methodology, Supervision, Writing - review & editing. **W.T. Johnston:** Formal analysis, Data curation, Visualization, Writing - original draft. **R. Newton:** Conceptualization, Funding acquisition, Methodology, Writing - review & editing.

Declaration of Competing Interest

None.

Acknowledgements

We thank our generous financial sponsors: Cancer Research UK for the study phase; for the continuation phase John Cheatham Foundation in Germany, Tijssen Foundation in the Netherlands, Associazione Medici Oculisti per l'Africa Italy, Fondazione Prosolidar Italy and Children with Cancer (UK). For support we thank the Administrative, Accounts, Information Technology and Pharmacy departments of Ruharo Eye Centre. For pathology we thank the histopathologists and laboratory technicians. Especially we thank the clinical officers, nurses, anaesthetic officers and operating theatre technicians for undertaking the heavy clinical workload to a high standard.

Appendix A. Supplementary data

Supplementary material related to this article can be found, in the online version, at doi:<https://doi.org/10.1016/j.canep.2020.101777>.

References

- N. Bhakta, L.M. Force, C. Allemani, R. Atun, F. Bray, M.P. Coleman, E. Steliarova-Foucher, A.L. Frazier, L.L. Robison, C. Rodriguez-Galindo, C. Fitzmaurice, Childhood cancer burden: a review of global estimates, *Lancet Oncol.* 20 (2019) e42–e53, [https://doi.org/10.1016/S1470-2045\(18\)30761-7](https://doi.org/10.1016/S1470-2045(18)30761-7).
- T. Kivelä, The epidemiological challenge of the most frequent eye cancer: retinoblastoma, an issue of birth and death, *Br. J. Ophthalmol.* 93 (2009) 1129–1131, <https://doi.org/10.1136/bjo.2008.150292>.
- K.M. Waddell, K. Kagame, A. Ndamira, A. Twinamasiko, S.V. Picton, I.G. Simmons, T. Johnston, R. Newton, Clinical features and survival among children with retinoblastoma in Uganda, *Br. J. Ophthalmol.* (2015) 387–390.
- W.T. Johnston, T.J. Lightfoot, J. Simpson, E. Roman, Childhood cancer survival: a report from the United Kingdom childhood Cancer study, *Cancer Epidemiol.* 34 (2010) 659–666, <https://doi.org/10.1016/j.canep.2010.06.020>.
- E. Broaddus, A. Topham, A.D. Singh, Survival with retinoblastoma in the USA: 1975–2004, *Br. J. Ophthalmol.* 93 (2009) 24–27, <https://doi.org/10.1136/bjo.2008.143842>.
- M. Sant, R. Capocaccia, V. Badioni, EURO CARE working group, survival for retinoblastoma in Europe, *Eur. J. Cancer* 37 (2001) (1990) 730–735, [https://doi.org/10.1016/s0959-8049\(01\)00011-9](https://doi.org/10.1016/s0959-8049(01)00011-9).
- K.M. Waddell, K. Kagame, A. Ndamira, A. Twinamasiko, S.V. Picton, I.G. Simmons, P. Revill, W.T. Johnston, R. Newton, Improving survival of retinoblastoma in Uganda, *Br. J. Ophthalmol.* 99 (2015) 937–942, <https://doi.org/10.1136/bjophthalmol-2014-306206>.
- G. Chantada, F. Doz, C.B.G. Antoneli, R. Grundy, F.F. Clare Stannard, I.J. Dunkel, E. Grabowski, C. Leal-Leal, C. Rodríguez-Galindo, E. Schwartzman, M.B. Popovic, B. Kremens, A.T. Meadows, J.-M. Zucker, A proposal for an international retinoblastoma staging system, *Pediatr. Blood Cancer* 47 (2006) 801–805, <https://doi.org/10.1002/pbc.20606>.
- A. Mallipatna, B.L. Gallie, P. Chévez-Barríos, L. Lumbroso-Le Rouic, G.L. Chantada, F. Doz, H.J. Brisse, F.L. Munier, D.M. Albert, J. Català-Mora, *Retinoblastoma, AJCC Cancer Staging Man.* 8 (2017) 819–831.
- C.L. Shields, A. Mashayekhi, A.K. Au, C. Czyn, A. Leahey, A.T. Meadows, J.A. Shields, The international classification of retinoblastoma predicts chemoreduction success, *Ophthalmology.* 113 (2006) 2276–2280, <https://doi.org/10.1016/j.ophtha.2006.06.018>.
- A. Linn Murphree, Intraocular retinoblastoma: the case for a new group classification, *Ophthalmol. Clin. N. Am.* 18 (2005) 41–53, <https://doi.org/10.1016/j.ophtha.2004.11.003>.
- T. Kivelä, E. Kujala, Prognostication in eye cancer: the latest tumor, node, metastasis classification and beyond, *Eye.* 27 (2013) 243–252, <https://doi.org/10.1038/eye.2012.256>.
- A. Dean, T. Arner, G. Sunki, R. Friedman, M. Lantinga, S. Sangam, J. Zubietta, K. Sullivan, K. Brendel, Z. Gao, N. Fontaine, M. Shu, G. Fuller, D. Smith, D. Nitschke, R. Fagan, *Epi Info, a Database and Statistics Program for Public Health Professionals*, CDC, Atlanta, GA, USA, 2011.
- SAS Institute Inc, *SAS software*, The SAS Institute, Cary, NC, USA, (2017).
- Global Retinoblastoma Study Group, I.D. Fabian, E. Abdallah, S.U. Abdullahi, R.A. Abdulqader, S. Adamou Boubacar, D.S. Ademola-Popoola, A. Adio, A.R. Afshar, P. Aggarwal, A.E. Aghaji, A. Ahmad, M.N.R. Akib, L. Al Harby, M.H. Al Ani, A. Alakbarova, S.A. Portabella, S.A.F. Al-Badri, A.P.A. Alcasabas, S.A. Al-Dahmash, A. Alejos, E. Alemany-Rubio, A.I. Alfa Bio, Y. Alfonso Carreras, C. Al-Haddad, H.H.Y. Al-Hussaini, A.M. Ali, D.B. Alia, M.F. Al-Jadiry, U. Al-Jumaly, H.M. Alkatan, C. All-Eriksson, A.A.R.M. Al-Mafrachi, A.A. Almeida, K.M. Alswaidi, A.A.S.M. Al-Shaheen, E.H. Al-Shammari, P.O. Amiruddin, R. Antonino, N.J. Astbury, H.T. Atalay, L.-O. Atchaneeyasakul, R. Atsiaya, T. Attaseth, T.H. Aug, S. Ayala, B. Baizakova, J. Balaguer, R. Balayeva, W. Balawierz, H. Barranco, C. Bascaran, M. Beck Popovic, R. Benavides, S. Benmiloud, N. Bennani Guebessi, R.C. Berete, J.L. Berry, A. Bhaduri, S. Bhat, S.J. Biddulph, E.M. Biewald, N. Bobrova, M. Boehme, H.C. Boldt, M.T.B.C. Bonanomi, N. Bornfeld, G.C. Bouda, H. Bouguila, A. Boumedane, R.C. Brennan, B.G. Brichard, J. Buaboonnam, P. Calderón-Sotelo, D.A. Calle Jara, J.E. Camuglia, M.R. Cano, M. Capra, N. Cassoux, G. Castela, L. Castillo, J. Català-Mora, G.L. Chantada, S. Chaudhry, S.S. Chaugule, A. Chauhan, B. Chawla, V.S. Chernodrina, F.S. Chiwanga, T. Chuluunbat, K. Cieslik, R.L. Cockcroft, C. Comsa, Z.M. Correa, M.G. Correa Llano, T.W. Corson, K.E. Cowan-Lyn, M. Csóka, X. Cui, I.V. Da Gama, W. Dangboon, A. Das, S. Das, J.M. Davanzo, A. Davidson, P. De Potter, K.Q. Delgado, H. Demirci, L. Desjarjans, R.Y. Diaz Coronado, H. Dimaras, A.J. Dodgshun, C. Donaldson, C.R. Donato Macedo, M.D. Dragomir, Y. Du, M.Du Bruyn, K.S. Edison, I.W. Eka Sutyawan, A. El Kettani, A.M. Elbahi, J.E. Elder, D. Elgalaly, A.M. Elhaddad, M.M.A. Elhassan, M.M. Elzembely, V.A. Essuman, T.G.A. Evina, Z. Fadoo, A.C. Fandiño, M. Faranoush, O. Fasina, D.D.P.G. Fernández, A. Fernández-Teijeiro, A. Foster, S. Frenkel, L.D. Fu, S.L. Fuentes-Alabi, B.L. Gallie, M. Gandiwa, J.L. García, D. García Aldana, P.Y. Gassant, J.A. Geel, F. Ghassemi, A.V. Girón, Z. Gizachew, M.A. Goenz, A.S. Gold, M. Goldberg-Lavid, G.A. Gole, N. Gomel, E. Gonzalez, G. Gonzalez Perez, L. González-Rodríguez, H.N. Garcia Pacheco, J. Graells, L. Green, P.A. Gregersen, N.D.A.K. Grigorovski, K.M. Guendon, D.S. Gunasekera, A.K. Gündüz, H. Gupta, S. Gupta, T. Hadjistilianou, P. Hamel, S.A. Hamid, N. Hamzah, E.D. Hansen, J.W. Harbour, M.E. Hartnett, M. Hasanreisoglu, S. Hassan, S. Hassan, S. Hederova, J. Hernandez, L.M.C. Hernandez, L. Hessissen, D.F. Hordofa, L.C. Huang, G.B. Hubbard, M. Hummlen, K. Husakova, A.N. Hussein Al-Janabi, R. Ida, V.R. Ilıc, V. Jairaj, I. Jeeva, H. Jenkinson, X. Ji, D.H. Jo, K.P. Johnson, W.J. Johnson, M.M. Jones, T.B.A. Kabesha, R.L. Kabore, S. Kaliki, A. Kalinaki, M. Kantar, L.-Y. Kao, T. Kardava, R. Kebudi, T. Kepak, N. Keren-Froim, Z.J. Khan, H.A. Khaqan, P. Khau, W.J. Kheir, V. Khetan, A. Khodabande, Z. Khotenashvili, J.W. Kim, J.H. Kim, H. Kiratli, T.T. Kivelä, A. Klett, J.E.K. Komba Palet, D. Krivaitiene, M. Kruger, K. Kulvichit, M.W. Kuntorini, A. Kyara, E.S. Lachmann, C.P.S. Lam, G.C. Lam, S.A. Larson, S. Latinovic, K.D. Laurenti, B.H.A. Le, K. Lecuona, A.A. Leverant, C. Li, B. Limbu, Q.B. Long, J.P. López, R.M. Lukamba, L. Lumbroso, S. Luna-Fineman, D. Lutfi, L. Lysytsia, G.N. Magrath, A. Mahajan, A.R. Majeed, E. Maka, M. Makan, E.K. Makimbetov, C. Manda, N. Martín Begue, L. Mason, J.O. Mason, I.O. Matende, M. Materin, C.C.D.S. Mattosinho, M. Matua, I. Mayet, F.B. Mbumba, J.D. McKenzie, A. Medina-Sanson, A. Mehrvar, A.A. Mengesha, V. Menon, G.J.V.D. Mercado, M.B. Mets, E. Midena, D.K.C. Mishra, F.G. Mndeme, A.A. Mohamedani, M.T. Mohammad, A.C. Moll, M.M. Montero, R.A. Morales, C. Moreira, P. Mruthyunjaya, M.S. Msina, G. Msukwa, S.S. Mudaliar, K.I. Muma, F.L. Munier, G. Murgoi, T.G. Murray, K.O. Musa, A. Mushtaq, H. Mustak, O.M. Muyen, G. Naidu, A.G. Nair, L. Naumenko, P.A. Ndoye Roth, Y.M. Nency, V. Neroev, H. Ngo, R.M. Nieves, M. Nikitovic, E.D. Nkanga, H. Nkumbe, M. Nuruddin, M. Nyaywa, G. Obono-Obiang, N.C. Oguego, A. Olechowski, S.C.N. Oliver, P. Osei-Bonsu, D. Ossandon, M.A. Paez-Escamilla, H. Pagarra, S.L. Painter, V. Paintsil, L. Paiva, B.P. Pal, M.S. Palanivelu, R. Papyan, R. Parrozzani, M. Parulekar, C.R. Parsical Morales, K.E. Paton, K. Pawinska-Wasikowska, J. Pe'er, A. Peña, S. Peric, C.T.M. Pham, R. Philbert, D.A. Plager, P. Pochoy, R.A. Polania, V.G. Polyakov, M.T. Pompe, J.J. Pons, D. Prat, V. Prom, I. Purwanto, A.O. Qadir, S. Qayyum, J. Qian, A. Rahman, S. Rahman, J. Rahmat, P. Rajkarnikar, R. Ramanjulu, A. Ramasubramanian, M.A. Ramirez-Ortiz, L. Raobela, R. Rashid, M.A. Reddy, E. Reich, L.A. Renner, D. Reynders, R. Ribadu, M.M. Riheia, P. Ritter-Sovinz, D. Rojanaporn, L. Romero, S.R. Roy, R.H. Saab, S. Saakyan, A.H. Sabhan, M.S. Sago, A.M.A. Said, R. Saiju, B. Salas, S. San Román Pacheco, G.L. Sánchez, P. Sayalith, T.A. Scanlan, A.C. Scheffer, J. Schoeman, A. Sedaghat, S. Seregard, R. Seth, A.S. Shah, S.A. Shakoob, M.K. Sharma, S.T. Sherief, N.G. Shetye, C.L. Shields, S.N. Siddiqui, S. Sidi Cheikh, S. Silva, A.D. Singh, N. Singh, U. Singh, P. Singha, R.S. Sitorus, A.H. Skalet, H.D. Soebagio, T. Sorochynska, G. Ssali, A.W. Stacey, S.E. Staffieri, E.D. Stahl, C. Stathopoulos, B. Stirn Kranj, D.K. Stones, C. Strahlendorf, M.E.C. Suarez, S. Sultana, X. Sun, M. Sundry, R. Superstein,

- E. Supriyadi, S. Surukrattanaskul, S. Suzuki, K. Svojgr, F. Sylla, G. Tamamyan, D. Tan, A. Tandili, F.F. Tarrillo Leiva, M. Tashvighi, B. Tateshi, E.S. Tehuteru, L.F. Teixeira, K.H. Teh, T. Theophile, H. Toledano, D.L. Trang, F. Traoré, S. Trichaiyaporn, S. Tuncer, H. Tyau-Tyau, A.B. Umar, E. Unal, O.E. Uner, S.F. Urbak, T.L. Ushakova, R.H. Usmanov, S. Valeina, M. van Hoefen Wijsard, A. Varadisai, L. Vasquez, L.O. Vaughan, N.V. Veleva-Krasteva, N. Verma, A.A. Victor, M. Viksnins, E.G. Villacís Chafra, V. Vishnevskia-Dai, T. Vora, A.E. Wachtel, W. Wackernagel, K. Waddell, P.D. Wade, A.H. Wali, Y.-Z. Wang, A. Weiss, M.W. Wilson, A.D.C. Wime, A. Wiwatwongwana, D. Wiwatwongwana, C. Wolley Dod, P. Wongwai, D. Xiang, Y. Xiao, J.C. Yam, H. Yang, J.M. Yanga, M.A. Yaqub, V.A. Yarovaya, A.A. Yarovoy, H. Ye, Y.A. Yousef, P. Yuliawati, A.M. Zapata López, E. Zein, C. Zhang, Y. Zhang, J. Zhao, X. Zheng, K. Zhilyaeva, N. Zia, O.A.O. Ziko, M. Zondervan, R. Bowman, Global retinoblastoma presentation and analysis by national income level, *JAMA Oncol.* (2020), <https://doi.org/10.1001/jamaoncol.2019.6716>.
- [16] G.L. Chantada, I. Qaddoumi, S. Canturk, V. Khetan, Z. Ma, K. Kimani, B. Yeniad, I. Sultan, R.S. Sitorus, N. Tacyildiz, D.H. Abramson, Strategies to manage retinoblastoma in developing countries, *Pediatr. Blood Cancer* 56 (2011) 341–348, <https://doi.org/10.1002/pbc.22843>.
- [17] S. Luna-Fineman, G. Chantada, A. Alejos, G. Amador, M. Barnoya, M.E. Castellanos, L. Fu, S. Fuentes-Alabi, V. Girón, M.A. Goenz, C. Maldonado, G. Méndez, R.A. Morales, R. Ortiz, G. Sanchez, M. Wilson, C. Rodríguez-Galindo, Delayed enucleation with neoadjuvant chemotherapy in advanced intraocular unilateral retinoblastoma: AHOPCA II, a prospective, multi-institutional protocol in Central America, *J. Clin. Oncol. Off. J. Am. Soc. Clin. Oncol.* 37 (2019) 2875–2882, <https://doi.org/10.1200/JCO.18.00141>.
- [18] G. Chantada, C. Leal-Leal, H. Brisse, P. de Graaf, R.S. Sitorus, I. Qaddoumi, C.B.G. de Antoneli, N. Tacyildiz, S.L. Fineman, L. Lumbroso, F. Doz, Is it pre-enucleation chemotherapy or delayed enucleation of severely involved eyes with intraocular retinoblastoma that risks extraocular dissemination and death? *J. Clin. Oncol.* 29 (2011) 3333–3334, <https://doi.org/10.1200/JCO.2011.35.9190>.
- [19] Uganda Bureau of Statistics – UBOS, (2019) (n.d.). <https://www.ubos.org/> (accessed January 18, 2019).
- [20] S. Kaliki, A. Patel, S. Iram, V.A.R. Palkonda, Clinical presentation and outcomes of stage III or stage IV retinoblastoma in 80 asian indian patients, *J. Pediatr. Ophthalmol. Strabismus* 54 (2017) 177–184, <https://doi.org/10.3928/01913913-20161019-01>.
- [21] D.H. Abramson, X. Ji, J.H. Francis, F. Catalanotti, S.E. Brodie, L. Habib, Intravitreal chemotherapy in retinoblastoma: expanded use beyond intravitreal seeds, *Br. J. Ophthalmol.* 103 (2019) 488–493, <https://doi.org/10.1136/bjophthalmol-2018-312037>.
- [22] J.H. Francis, S.E. Brodie, B. Marr, E.C. Zabor, I. Mondesire-Crump, D.H. Abramson, Efficacy and toxicity of intravitreal chemotherapy for retinoblastoma: four-year experience, *Ophthalmology* 124 (2017) 488–495, <https://doi.org/10.1016/j.optha.2016.12.015>.