

# Safety profile of *Colocasia esculenta* tuber extracts in benign prostate hyperplasia

**Deusdedit Tusubira** (✉ [dtusubira@must.ac.ug](mailto:dtusubira@must.ac.ug))

Mbarara University of Science and Technology

**Patrick M. Aja**

Mbarara University of Science and Technology

**Jonasi Munezero**

Mbarara University of Science and Technology

**Frank Ssedyabane**

Mbarara University of science and Technology

**Nathim Namale**

Mbarara University of Science and Technology

**Josiah . E. Ifie**

Kampala International University

**Peter C Agu**

Ebonyi State University

**Clement O. Ajayi**

Mbarara University of Science and Technology

**Joash Okoboi**

Soroti University

---

## Research Article

### Keywords:

**Posted Date:** August 30th, 2022

**DOI:** <https://doi.org/10.21203/rs.3.rs-1930275/v1>

**License:**   This work is licensed under a Creative Commons Attribution 4.0 International License.

[Read Full License](#)

---

# Abstract

**Introduction:** This study was motivated by the increasing global incidence of benign prostatic hyperplasia (BPH) and the promising potential of nutraceuticals as complementary therapies in ameliorating its burden. We report the safety profile of *Colocasia esculenta* tuber extracts, a novel nutraceutical in benign prostate hyperplasia in a rat model.

**Methods:** In our study, forty-five male albino rats were randomly assigned into 9 groups of 5 rats each. Group 1 (normal control) received olive oil and normal saline. Group 2 (negative control) received 3 mg/kg of testosterone propionate (TP) and normal saline, group 3 (positive control) received 3mg/kg of TP and 5 mg/kg of finasteride. Our treatments groups 4, 5, 6, 7, 8 and 9 received 3 mg/kg of TP and lower dose (100 mg/kg) of LD<sub>50</sub> of ethanol crude tuber extract of *Colocasia esculenta* (ECTECE) or hexane, dichloromethane, butanone, ethylacetate and aqueous fractions of ECTECE respectively for a period of 28 days.

**Results:** The negative controls showed significant ( $p < 0.05$ ) increase in mean prostate weight (approximately 5 times) as well as reduction in relative testes weight (approximately 1.4 time less). There was no significant ( $p > 0.05$ ) difference in mean relative weights of most vital organs: liver, kidneys and heart. This was also observed in hematological parameters: RBC, hemoglobin, HCT, MCV, MCH, MCHC and platelets counts. In general, we note that the effects of the well-established drug finasteride on the biochemical parameters and histology of selected organs are comparable to those of *c. esculenta* fractions.

**Conclusion:** This study demonstrates safety potential of *C. esculenta* tuber extract in a rat model.

## Introduction

The increasing trend of life expectancies across the world [1] has been accompanied by increasing prevalence and incidence of benign prostate hyperplasia (BPH) [2–4]. Benign prostate hyperplasia as defined histologically by an overgrowth of prostate tissue [5], is among the commonest noncancerous form of abnormal prostate cell growth affecting older men globally [6–8]. In men over 50 years of age, global prevalence of BPH ranges between 20 to 62% [4, 9–11]. As the prostate enlarges, it constricts the urethra leading to symptoms which usually result into BPH associated lower urinary tract symptoms (LUTS) [2, 8, 12, 13]. In Uganda, the prevalence rates for LUTS in men above 55 years of age were estimated to be as high as 40.5% in a study published in 2018 [14]. Apart from the cost [10, 15] and health systems challenges, poor treatment outcomes in BPH have been linked to real and perceived side effects of commonly used pharmacological regimens [15–18].

Conventional pharmacological management of BPH usually involves use of alpha-blockers comprising alpha-adrenoceptor antagonists, or 5-alpha-reductase inhibitor or a combination of both [15, 17, 19]. These treatment options are associated with severe side effects including but not limited to organ toxicity and sexual dysfunction [20–22]. Moreover most of these patients are older adults with multiple co-

morbidities and medications [23]. There is an urgent need for additional research into novel approaches to treatment of BPH which could involve incorporation of alternative or complementary therapies [8].

There are vast quantities of unexplored novel phytotherapeutic agents from commonly consumed foods that could provide better options for management and/or prevention of BPH [24, 25]. Such options are usually associated with fewer side effects due to long history of traditional use as foods [24] although more data is required to get a better understanding of their safety profiles [26]. *C. esculenta* (English name cocoyam or Taro, local name in Buganda region of Uganda, 'Obukopa' and in Igbo (*Onitsha*) Nigeria is among the neglected but important foods across the African continent [27–29] traditionally used in the management of BPH in many West African countries [29–31]. Medicinal properties of *C. esculenta* *in vitro* and *in vivo* have previously been reviewed by Prajapati *et al* (2011) [29]. Moreover studies by Brown *et al* (2005) suggest that *C. esculenta* has novel tumor specific anti-cancer activities on rat YTT colon cancer cell line [32]. Furthermore, using animal models, Kalariya *et al* (2015) [33] reported that (25 and 50 mg/kg, i.p.) of hydroalcoholic extract of leaves of *C. esculenta* decreases obsessive-compulsive disorder in mice. Some studies have also demonstrated the anti-diabetic properties of *C. esculenta* tuber and leaves in rat model [34–37].

Previous studies by Eleazu and others [38] based on a rat animal model demonstrated that *C. esculenta* contains anti-inflammatory agents that may remediate BPH associated inflammation. Studies by Nzebang *et al* (2018) [39] suggest that the aqueous extract from *C. esculenta* leaves infected by *Phytophthora colocasiae* would be no major health risk with estimated LD<sub>50</sub> of more than 4000 mg/kg in rats. Although our previous studies have demonstrated that the ethanol crude extract of *C. esculenta* has the capacity to reduce prostate weight, total protein as well as serum concentration of prostate specific antigen [40] there was need to further explore the safety profile and associated biochemical mechanisms. This study was therefore designed to investigate the safety profile of *C. esculenta* in crude and semi purified form for the management and / or prevention of BPH.

## Materials And Methods

**Collection and Identification of Plant Materials:** Mature (6-8 months old) fresh tubers of *C. esculenta* were collected with permission from the selected farmers and local authorities including agricultural extensions officer as guided by the Office of Research, Innovation and Institutional Ethics Committee of Ebonyi state university, Nigeria (EBSU/BCH/ET/21/001). This was done in accordance with guidelines from the Nigerian Federal Environmental Protection Agency and the International Union for Conservation of Nature (IUCN) policy on Research Involving Species at Risk of Extinction. This was followed by authentication by a taxonomist, Professor S.O. Onyekwelu at the department of Applied Biology, Ebonyi state University (*Colocasia esculenta* (L) Schott, Family *Araceae*, common name: Cocoyam Local name; *Ede ofe*, voucher number: EBSU-H-206, Department of applied biology herbarium, Ebonyi State university, Nigeria ; Herbarium curator, Mr Nwanko Onyebuchi Ephraim).

**Preparation of Plant Materials:** *C. esculenta* tubers were washed, boiled, peeled, sliced into chips, air-dried to a constant weight at a room temperature and processed into flour.

**Extraction of Plant Materials:** The powdered tuber 1280g of *C. esculenta* were extracted with 8 L of 50% ethanol (Emsure®) overnight in a big stopper bottle with occasional stirring at room temperature. It was then sieved using muslin cloth. The filtrates were air dried for 24 h to get the ethanol (crude) extracts.

**Purification by Solvent extraction using partition coefficient:** The crude natural ethanol product was extracted with solvents of increasing polarity, first, hexane (Blulux), dichloro methane (UNILAB), ethyl acetate (UNILAB) and butanol (AnalaR®) which depended on the chemical and physical nature of the target compounds.

This study was done under the supervision and approval by the Office of Research, Innovation and Institutional Ethics Committee of Ebonyi state university, Nigeria (EBSU/BCH/ET/21/001). All procedures for animal studies were performed following guidelines and legislations consistent with the National Institute of Health Guide for the Care and Use of Laboratory Animals (NIH Publications No. 80-23, revised in 1996) [33] as well as the National guidelines for the use of laboratory animals for research and teaching based on the principles of 3Rs, reduce refine or replace.

### **Laboratory animals**

The study used 45 male Wistar albino rats of about 6 weeks old which were sourced from the Animal House of Ebonyi state university, Nigeria. They were kept in stainless cages (size: 16 x 9 = 144inches) in a well-ventilated animal house. They were acclimatized for seven days under good laboratory conditions (12 hours light/dark cycle; room temperature) before the start of the experiments. All animals were allowed free access to standard rodent chow and water *ad libitum*. All animals were humanely sacrificed using halothane.

### **Induction of Benign Prostatic Hyperplasia**

We induced Benign Prostatic Hyperplasia in rats using testosterone propionate (TP) [34, 35]. The dose for induction was formulated as 3mg/kg body weight and it was given by subcutaneous injection every day for 28 days. We prepared stock by dissolving 25mg of TP in 8.33ml olive oil. Three rats each from the groups were randomly selected after induction for confirmation of BPH before treatment.

### **Grouping of animals**

The rats were grouped as follows, with five rats in each group: Rats in group 1 (Normal control) received orally 1ml of olive oil. BPH was induced in groups 2-9 with 3 mg/kg TP subcutaneously. Group 2 (BPH group) was not treated. Group 3 (Finasteride group) had rats which were treated with 5mg/kg finasteride. The middle dose of 200 mg/kg was used for this study as reported by Eleazu *et al.* (2021). Group 4 had rats which were treated with 200 mg/kg body weight (b.w) of ethanol crude tuber extract of *C. esculenta* (ECTECE). Group 5 had rats that were treated with 200 mg/kg b.w of n-hexane fraction (HF).

Group 6 had rats that were treated with 200 mg/kg b.w of dichloromethane fraction (DCMF). Group 7 had rats that were treated with 200 mg/kg b.w of ethyl acetate fraction (EAF). Group 8 had rats that were treated with 200 mg/kg b.w of butanone fraction (BF). And finally, group 9 had rats that were treated with 200 mg/kg b.w of aqueous fraction (AF). Oral administration of the extract or fractions or finasteride was done using oral gavage and all animal diets were provided *ad libitum*

### **Laboratory analysis**

After 28 days, the rats were fasted overnight, sacrificed after being anesthetized with halothane and dissected to collect vital organs which included liver, kidney, heart as well as prostate and testes. All organs were weighed and immediately placed in 10% neutral buffered formalin for fixation until histopathological examination. We also collected blood samples from animals by cardiac puncture, using 5ml syringes into EDTA vacutainers for complete blood count. Anticoagulated blood samples were stored at 2 to 8<sup>0</sup>c for two days after which a complete blood count was performed.

For complete blood count, we used a five-part differential fully automated analyser, Sysmex XN550, Japan. Sample tubes with caps closed were placed in sample adapters. We then used the start/stop switch to execute automatic sample mixing, aspiration, analysis and printing of results.

### **Histopathological examination**

The histopathological examination of the organs was done by the method of Lee *et al.* (2017). Tissues were grossed and small pieces were cut out and placed in tissue cassettes for processing. Tissue processing included completion of fixation in 10% neutral buffered formalin, dehydration in increasing concentrations of ethanol, clearing in two changes of xylene and impregnation with molten paraffin wax. Tissues were then embedded using Tissue-Tek embedding moulds and sectioned using a microtome set at 5µm. Tissue sections were stained using the Haematoxylin and Eosin (H and E) stain and later examined under a microscope.

### **Quality control**

For the complete blood count, we used control blood and normal samples to monitor daily variation. We also employed the XN check levels 1, 2 and 3. In addition, we followed manufacturer's instruction and standard operating procedures for equipment start-up, self-check, as well as sample preparation and loading.

For histopathology, we ensured use of standard operating procedures and all stains and reagents were used after filtration. Examination of slides was done by two qualified pathologists and in cases of a discrepancy, a third pathologist was involved

### **Statistical data analyses**

Data were analyzed using Prism software (Graph-Pad Software; San Diego, CA) to determine statistical significance. The results are shown as mean  $\pm$  SD of 5 rats per group.  $P < 0.05$  was considered statistically significant

## Results

### ***C. esculenta* protection against BPH is comparable to finasteride**

We observed an increase in serum total protein as induced by *C. esculenta* fractions comparable to that induced by standard treatment (finasteride) (Fig. 1). The same was observed in mean total body weight of the animals in each group ( Fig. 2B). While the mean relative prostate weights significantly increased (approximately 5 times  $P < 0.05$ ) (Fig. 2A) on treatment with testosterone propionate, this increase was moderated by *C. esculenta* extracts to levels comparable to that achieved by finasteride.

### **Ethanol crude Tuber extract of *C. esculenta* and Fractions protects vital organs in Testosterone propionate (TP) induced benign prostate hyperplastic (BPH) Rats.**

Administration of TP in male Wistar albino rats showed no significant ( $p > 0.05$ ) difference on the relative liver, kidneys and heart weights although there was a significant ( $p < 0.05$ ) reduction in mean relative testes weight (approximately 1.4 times less) (Fig. 3(a-d)). Co-administration of TP and ethanol crude Tuber extract of *C. esculenta* (ECTECE), hexane fraction (HF), dichloromethane fraction (DCMF), butanone fraction (BF), Ethyl acetate fraction(EAF) and aqueous fraction(AF) showed no significant ( $p < 0.05$ ) difference on the relative organs weights(Fig. 3(a-d)).

### **Effect of ethanol crude Tuber extract of *C. esculenta* and Fractions on Red blood cell and Platelet counts**

Administration of TP in male Wistar albino rats showed no significant ( $p > 0.05$ ) difference on RBC, haemoglobin, HCT, MCV, MCH, MCHC and platelets levels (Fig. 4(a-g)). Co-administration of TP and ethanol crude Tuber extract of *C. esculenta* (ECTECE), hexane fraction (HF), dichloromethane fraction (DCMF), butanone fraction (BF), Ethyl acetate fraction(EAF) and aqueous fraction(AF) in male rats showed no significant( $p < 0.05$ ) difference on the haematological parameters as shown in Fig. 4(a-g). A significant ( $p < 0.05$ ) reduction in MCV level was recorded in the group that received TP + ECTECE while significant differences were recorded in groups that received TP + Finasteride and TP + AF (Fig. 4g).

### **Effect of ethanol crude Tuber extract of *C. esculenta* and Fractions on Red Blood cells and Leukocyte counts**

Administration of TP in male Wistar albino rats significantly ( $p > 0.05$ ) reduced the WBC, monocytes and lymphocytes counts with a significant ( $p < 0.05$ ) elevation on the counts of neutrophils, eosinophil and basophiles (Fig. 5 (a-f)). Co-administration of TP and ethanol crude Tuber extract of *C. esculenta* (ECTECE), hexane fraction (HF), dichloromethane fraction (DCMF), butanone fraction (BF), Ethyl acetate fraction (EAF) and aqueous fraction (AF) in male rats significantly ( $p < 0.05$ ) elevated the counts of WBC,

monocytes and lymphocytes with significantly ( $p < 0.05$ ) reduced neutrophil, eosinophil and basophil counts as shown in Figs. 5. There was no significant ( $p > 0.05$ ) difference on WBC counts in group that received TP + ECTECE and non-significant ( $p > 0.05$ ) difference on lymphocyte counts (Fig. 5(a-f)).

### **Effect of ethanol crude Tuber extract of *Colocasia esculenta* and Fractions on Histopathological features of the Prostate Gland**

The results of histopathological examination of the prostate glands of the rats that were studied are shown in Fig. 6. Histopathological examination of the prostates of the control (Fig. 6 (I)) revealed no demonstrable prostatic hyperplasia and increased reduction in the number of cells that rimmed the prostatic gland with no proliferation of the glandular cells of the prostate. The group that received TP + finasteride group showed demonstrable prostatic hyperplasia as well as mild proliferation of the glandular cells of the prostate as shown in Fig. 6(II). The group that received TP + ECTECE (Fig. 6(III)) showed a mild proliferation of the glandular cells of the prostate and evidence of reduced production of prostatic gland fluids. There was also normal prostate gland and increased reduction of the number of cells that rimmed the prostate gland with increased eosinophilic secretions at the center. And finally, BPH group showed increased proliferation, multiplication of the prostate gland and demonstrable hyperplasia (Fig. 6(IV)).

### **Effect of ethanol crude Tuber extract of *C. esculenta* and Fractions on Histopathological features of liver**

Liver histopathological examination showed no demonstrable features of hyperplasia, hypertrophy or atrophy in biopsies obtained from the normal control (Fig. 7 (I.NC)), BPH group (Fog. 7(II.BPH)) as well as in the group that received TP + ECTECE (Plate2 (III)). This demonstrated the safety of the extract to the liver. The only observed feature was congestion as shown in Fig. 7 (I-III).

### **Effect of ethanol crude Tuber extract of *C. esculenta* and Fractions on Histopathological features of heart**

Figure 8 (I-IV). Haematoxylin and Eosin stain on histological sections of heart tissue. (I) Normal control (NC)group (magnification, x200); (II) BPH control group (magnification, x200); (III) TP + Finasteride (magnification, x200) and (iv) TP + ECTECE (magnification, x200). BPH- Benign prostatic hyperplasia, ethanol crude tuber extract of *C. esculenta*

### **Effect of ethanol crude Tuber extract of *C. esculenta* and Fractions on Histopathological feature of kidneys**

Histopathological examination of kidney tissue showed no demonstrable features of hyperplasia, hypertrophy or atrophy in biopsies obtained from the normal control, BPH control group, TP + Finasteride and TP + ECTECE as shown in Fig. 9 (I-IV). This demonstrated the safety of the extract to the kidneys.

## **Discussion**

This study was aimed at investigating the safety profile of *C. esculenta* in crude and semi purified form for the management and or prevention of BPH. Our results show that *C. esculenta* is effective and widely tolerated as an anti BPH nutraceutical in the rat model. Moreover, it has been reported to contain over 64.37% 9-Octadecenoic acid (C<sub>18</sub>H<sub>34</sub>O<sub>2</sub>) [41]. Octadecenoic acid, is an important bioactive component of *C. esculenta* with anti-inflammatory, anti-alopecic, 5- $\alpha$ -reductase inhibitory, anemiagenic, anti-tumour, immuno-stimulatory, anti-leucotriene-D<sub>4</sub>, anti-androgenic, lipoxygenase inhibitory and hypocholesterolemic properties[40].

Data from the biochemical and hematological parameters of our study do not show evidence of toxicity. However, we observed decrease in body weights of the treatment group. This is suggestive of a potential cellular response to arrest BPH through breakdown of tissue proteins [40]. In addition, we observed, an increase in the body weights of the groups that received finasteride, or ethanol crude tuber extract of *Colocasia esculenta* (ECTECE) or hexane, dichloromethane, butanone, ethyl acetate and aqueous fractions of ECTECE which suggest a dose dependent action by the crude extract and fractions of ECTECE in halting the breakdown of tissue proteins.

More to this the elevated prostate weights as observed in the BPH group could have resulted from pathological alterations in the prostatic tissue linked to BPH [40, 42]. However, the lower relative prostate weights of the BPH + finasteride, BPH + ECTECE, or BPH + hexane, dichloromethane, butanone, ethyl acetate and aqueous fractions of ECTECE groups indicate that these treatments may be able to reduce prostatic hyperplasia at the lower doses utilized in this investigation. Although we cannot rule out the possibility that increase in body weights of some rats contributed to the decrease in relative prostate weights, given that their bodyweights were much higher than those of the BPH group.

According to the present study, non-significant ( $p > 0.05$ ) differences in relative liver, kidney and heart weights were observed in both BPH group and the treated groups. This non-significant difference in the relative's organs weight may demonstrate nontoxic effect of the crude extract of cocoyam and fractions to the organs[43, 44]. This particular result confirms a previous report by Eleazu *et al.* (2013) [43] which showed no significant differences ( $P > 0.05$ ) in the liver, kidney and heart weights of the diabetic rats administered cocoyam feed and diabetic control rats. Eleazu *et al.* (2014) [36] which reported that the diabetic rats fed with cocoyam had significant elevation ( $P < 0.05$ ) of hepatic AST, ALT, ALP and serum proteins and albumin, but had significant reduction ( $P < 0.05$ ) of blood glucose, serum urea, creatinine, amylase, lipase, AST, ALT and ALP compared with the diabetic control rats also support the safety of cocoyam in the management of diseases.

Reduction in the testes weight in the BPH group as observed in this study could be as a result of exogenous effect of TP as a potential male contraceptive[45]. On the contrary the study revealed that crude extract cocoyam tuber and fractions were able to modulate the negative effect on the testes weight.

Increased counts of neutrophils, eosinophils, basophils and reduction in white blood cell, monocytes and lymphocytes counts; no significant ( $p > 0.05$ ) difference on RBC, haemoglobin, HCT, MCV, MCH, MCHC

and platelets counts could be attributed to the BPH induction in BPH group. The treatment with crude extract of cocoyam tuber and fractions modulated the immune and haematological parameters showing the safety of the cocoyam extract and fractions. This result is similar with Princewill-Ogbonna *et al.* (2016) [46] which reported non-significant difference in haematological parameters in rats feed with cocoyam made feed. Azubuike *et al.* (2018) [44] also reported the safety of usage of *C. esculenta* leaves in the reduction of fat adipose tissues and its ameliorative effect on HFD-induced liver damage.

## Conclusion And Recommendation

. We recommend further studies on mechanism and active components responsible for anti BPH activity of *C.esculenta*.

## Declarations

### Ethics approval and consent to participate

This study was done under the supervision and approval by the Office of Research, Innovation and Institutional Ethics Committee of Ebonyi state university, Nigeria (EBSU/BCH/ET/21/001). All procedures for animal studies were carried out and reported based on the Animal Research: Reporting of In Vivo Experiments (ARRIVE) guidelines and legislations consistent with the National Institute of Health Guide for the Care and Use of Laboratory Animals (NIH Publications No. 80-23, revised in 1996) [33] as well as National guidelines for the use of laboratory animals for research and teaching based on the principles of 3Rs, reduce refine or replace.

### Consent for publication

Not applicable

### Availability of data and materials

All data generated or analyzed during this study are included in this published article.

### Competing interests

I declare that the authors have no competing interests as defined by BMC, or other interests that might be perceived to influence the results and/or discussion reported in this paper

### Funding

There was no funding of any of the authors for this project.

### Authors' contributions

DT, PMA conceived the idea., DT, PMA, JM, FS, NN, JEI, COA, and JO designed experiments, carried out laboratory work, analyzed data, PMA wrote the first draft of the manuscript, and all members revised and contributed to the final version of the manuscript.

## Acknowledgements

We acknowledge contributions of laboratory technicians at Ebonyi state University and Mbarara University of science and technology including Mr. Mutekanga Emanuel, Mr Mukundane Victor and Mr Rujumba Bright. The DAAD staff exchange fellowship for sub-Saharan Africa that provided Dr Patrick M. Aja an opportunity to visit Mbarara University during this project. We also acknowledge technical support from Mr Joseph Oloro and support in terms of infrastructure of specific universities including Mbarara and Ebonyi state University and Kampala International University.

## References

1. **Global, regional, and national age-sex-specific mortality and life expectancy, 1950-2017: a systematic analysis for the Global Burden of Disease Study 2017.** *Lancet (London, England)* 2018, **392**(10159):1684-1735.
2. Chughtai B, Forde JC, Thomas DDM, Laor L, Hossack T, Woo HH, Te AE, Kaplan SA: **Benign prostatic hyperplasia.** *Nature reviews Disease primers* 2016, **2**(1):1-15.
3. Sohlberg EM, Thomas IC, Yang J, Kapphahn K, Daskivich TJ, Skolarus TA, Shelton JB, Makarov DV, Bergman J, Bang CK *et al.* **Life expectancy estimates for patients diagnosed with prostate cancer in the Veterans Health Administration.** *Urologic oncology* 2020, **38**(9):734.e731-734.e710.
4. Launer BM, McVary KT, Ricke WA, Lloyd GL: **The rising worldwide impact of benign prostatic hyperplasia.** 2021, **127**(6):722-728.
5. Barry MJ, Roehrborn CG: **Benign prostatic hyperplasia.** *Bmj* 2001, **323**(7320):1042-1046.
6. Gossel TA, Wuest JR: **New drugs of 2004 for treatment of benign prostatic hyperplasia: Avodart and Uroxatal.** *Contin Educ Pharm* 2004, **22**:1-4.
7. Ng M, Baradhi KM: **Benign prostatic hyperplasia.** 2020.
8. Lokeshwar SD, Harper BT, Webb E, Jordan A, Dykes TA, Neal Jr DE, Terris MK, Klaassen Z: **Epidemiology and treatment modalities for the management of benign prostatic hyperplasia.** *Translational andrology and urology* 2019, **8**(5):529.
9. Chokkalingam AP, Yeboah ED, Demarzo A, Netto G, Yu K, Biritwum RB, Tettey Y, Adjei A, Jadallah S, Li Y *et al.* **Prevalence of BPH and lower urinary tract symptoms in West Africans.** *Prostate cancer and prostatic diseases* 2012, **15**(2):170-176.
10. Yeboah ED: **PREVALENCE OF BENIGN PROSTATIC HYPERPLASIA AND PROSTATE CANCER IN AFRICANS AND AFRICANS IN THE DIASPORA.** *Journal of the West African College of Surgeons* 2016, **6**(4):1-30.

11. Peter N, Michael C: **Benign Prostatic Hyperplasia (BPH) in an elderly Ugandan male.** *MMJ* 2014, **46**(1).
12. Pais P: **Potency of a novel saw palmetto ethanol extract, SPET-085, for inhibition of 5 $\alpha$ -reductase II.** *Advances in therapy* 2010, **27**(8):555-563.
13. Roehrborn CG: **Male lower urinary tract symptoms (LUTS) and benign prostatic hyperplasia (BPH).** *Medical Clinics* 2011, **95**(1):87-100.
14. Bajunirwe F, Stothers L, Berkowitz J, Macnab AJ: **Prevalence estimates for lower urinary tract symptom severity among men in Uganda and sub-Saharan Africa based on regional prevalence data.** *Canadian Urological Association journal = Journal de l'Association des urologues du Canada* 2018, **12**(11):E447-e452.
15. Corona G, Rastrelli G, Maseroli E, Balercia G, Sforza A, Forti G, Mannucci E, Maggi M: **Inhibitors of 5 $\alpha$ -reductase-related side effects in patients seeking medical care for sexual dysfunction.** *Journal of endocrinological investigation* 2012, **35**(10):915-920.
16. Ogunbiyi OJ: **Impact of health system challenges on prostate cancer control: health care experiences in Nigeria.** *Infectious Agents and Cancer* 2011, **6**(2):S5.
17. Yu Z-J, Yan H-L, Xu F-H, Chao H-C, Deng L-H, Xu X-D, Huang J-B, Zeng T: **Efficacy and side effects of drugs commonly used for the treatment of lower urinary tract symptoms associated with benign prostatic hyperplasia.** *Frontiers in Pharmacology* 2020, **11**:658.
18. Emberton M, Marberger M, de la Rosette J: **Understanding patient and physician perceptions of benign prostatic hyperplasia in Europe: The Prostate Research on Behaviour and Education (PROBE) Survey.** *International journal of clinical practice* 2008, **62**(1):18-26.
19. Ückert S, Kedia GT, Tsikas D, Simon A, Bannowsky A, Kuczyk MA: **Emerging drugs to target lower urinary tract symptomatology (LUTS)/benign prostatic hyperplasia (BPH): focus on the prostate.** *World journal of urology* 2020, **38**(6):1423-1435.
20. Dunn MW, Kazer MW: **Prostate cancer overview.** In: *Seminars in oncology nursing: 2011*: Elsevier; 2011: 241-250.
21. Silva J, Silva CM, Cruz F: **Current medical treatment of lower urinary tract symptoms/BPH: do we have a standard?** *Curr Opin Urol* 2014, **24**(1):21-28.
22. Van Asseldonk B, Barkin J, Elterman DS: **Medical therapy for benign prostatic hyperplasia: a review.** *Can J Urol* 2015, **22 Suppl 1**:7-17.
23. Saka SA, Yusuf AA, Campus S: **Drug therapy problem in elderly outpatients with benign prostatic hyperplasia.** *West African Journal of Pharmacy* 2021, **32**(1):33-44.
24. Eleazu C, Eleazu K, Kalu W: **Management of benign prostatic hyperplasia: Could dietary polyphenols be an alternative to existing therapies?** *Frontiers in pharmacology* 2017, **8**:234.
25. Cicero AFG, Allkanjari O, Busetto GM, Cai T, Larganà G, Magri V, Perletti G, Robustelli Della Cuna FS, Russo GI, Stamatiou K *et al*: **Nutraceutical treatment and prevention of benign prostatic hyperplasia and prostate cancer.** *Archivio italiano di urologia, andrologia : organo ufficiale [di] Societa italiana di ecografia urologica e nefrologica* 2019, **91**(3).

26. Curtis Nickel J, Shoskes D, Roehrborn CG, Moyad M: **Nutraceuticals in Prostate Disease: The Urologist's Role.** *Reviews in urology* 2008, **10**(3):192-206.
27. Talwana H, Serem A, Ndabikunze B, Nandi J, Tumuhimbise R, Kaweesi T, Chumo C, Palapala VA: **Production Status and Prospects of Cocoyam (*Colocasia esculenta* L. Schott.) in East Africa.** 2009.
28. Otekunrin OA, Sawicka B, Adeyonu AG, Otekunrin OA, Rachoń L: **Cocoyam [*Colocasia esculenta* (L.) Schott]: Exploring the Production, Health and Trade Potentials in Sub-Saharan Africa.** *Sustainability* 2021, **13**(8):4483.
29. Prajapati R, Kalariya M, Umbarkar R, Parmar S, Sheth N: ***Colocasia esculenta*: A potent indigenous plant.** *International Journal of Nutrition, Pharmacology, Neurological Diseases* 2011, **1**(2):90.
30. Mitsunari K, Miyata Y, Matsuo T, Mukae Y, Otsubo A, Harada J, Kondo T, Matsuda T, Ohba K, Sakai H: **Pharmacological Effects and Potential Clinical Usefulness of Polyphenols in Benign Prostatic Hyperplasia.** *Molecules* 2021, **26**(2):450.
31. Keerthy S, Joshi KH: **The pharmacological importance of *Colocasia esculenta* Linn: A review.** *Journal of Pharmacognosy and Phytochemistry* 2019, **8**(6):1945-1948.
32. Brown AC, Reitzenstein JE, Liu J, Jadus MR: **The anti-cancer effects of poi (*Colocasia esculenta*) on colonic adenocarcinoma cells *in vitro*.** *Phytotherapy research : PTR* 2005, **19**(9):767-771.
33. Kalariya M, Prajapati R, Parmar SK, Sheth N: **Effect of hydroalcoholic extract of leaves of *Colocasia esculenta* on marble-burying behavior in mice: Implications for obsessive-compulsive disorder.** *Pharmaceutical biology* 2015, **53**(8):1239-1242.
34. Islam MH, Mostafa MN, Rahmatullah M: **Antihyperglycemic activity of methanolic extracts of corms of *Colocasia esculenta* var *esculenta*.** *Eur J Pharm Med Res* 2018, **5**(3):129-132.
35. Tripathi AK, Kohli S: **Phytochemical screening and evaluation of antidiabetic activity of *Colocasia esculenta* (L) leaves on STZ induced diabetic rats.** *Advances in Pharmacology and Toxicology* 2013, **14**(2):1.
36. Eleazu CO, Okafor PN, Ifeoma I: **Biochemical basis of the use of cocoyam (*Colocassia esculenta* L.) in the dietary management of diabetes and its complications in streptozotocin induced diabetes in rats.** *Asian Pacific Journal of Tropical Disease* 2014, **4**:S705-S711.
37. Shithi S, Mohammed R: **Antihyperglycemic and antinociceptive activities of methanolic extract of *Colocasia esculenta* (L.) Schott stems: a preliminary study.** *American-Eurasian Journal of Sustainable Agriculture* 2013, **7**(4):314-319.
38. Eleazu C: **Characterization of the natural products in cocoyam (*Colocasia esculenta*) using GC–MS.** *Pharmaceutical biology* 2016, **54**(12):2880-2885.
39. Nyonseu Nzebang DC, Ngaha Njila MI, Bend EF, Oundoum Oundoum PC, Koloko BL, Bogning Zanguéu C, Belle Ekedí P, Sameza M, Massoma Lembè D: **Evaluation of the toxicity of *Colocasia esculenta* (Aracaceae): Preliminary study of leaves infected by *Phytophthora colocasiae* on wistar albinos rats.** *Biomedicine & pharmacotherapy = Biomedecine & pharmacotherapie* 2018, **99**:1009-1013.

40. Eleazu K, Maduabuchi Aja P, Eleazu CO: **Cocoyam (*Colocasia esculenta*) modulates some parameters of testosterone propionate-induced rat model of benign prostatic hyperplasia.** *Drug and Chemical Toxicology* 2021;1-11.
41. Omotoso Abayomi E, Kenneth E, Mkpuru K: **Chemometric profiling of methanolic leaf extract of *Cnidioscolus aconitifolius* (Euphorbiaceae) using UV-VIS, FTIR and GC-MS techniques.** *J Med Plants Res* 2014, **2**(1):6-12.
42. Kalu W, Okafor P, Ijeh I, Eleazu C: **Effect of kolaviron, a biflavanoid complex from *Garcinia kola* on some biochemical parameters in experimentally induced benign prostatic hyperplastic rats.** *Biomedicine & pharmacotherapy* 2016, **83**:1436-1443.
43. Eleazu CO, Iroaganachi M, Eleazu K: **Ameliorative potentials of cocoyam (*Colocasia esculenta* L.) and unripe plantain (*Musa paradisiaca* L.) on the relative tissue weights of streptozotocin-induced diabetic rats.** *Journal of diabetes research* 2013, **2013**.
44. Azubuike NC, Onwukwe OS, Onyemelukwe AO, Maduakor UC, Ifeora IM, Okwuosa CN, Achukwu PU: **Impact of *Colocasia esculenta* extract and fractions on high-fat diet-induced changes in body weight, adipose tissue and liver of rats.** *Pakistan Journal of Pharmaceutical Sciences* 2018.
45. Van ROIJEN JH, OOMS MP, WEBER RF, BRINKMANN AO, GROOTEGOED JA, VREEBURG JT: **Comparison of the response of rat testis and accessory sex organs to treatment with testosterone and the synthetic androgen methyltrienolone (R1881).** *Journal of andrology* 1997, **18**(1):51-61.
46. Princewill-Ogbonna IL, Ihedioha, S and Ijeoma, S. N.: **Hematological and liver/Kidney Histology of rats feed with cocoyam (*Colocasia esculenta* L.).** *Contemporary journal of Empirical Research*, 2016, **2**(3):271-287.

## Figures

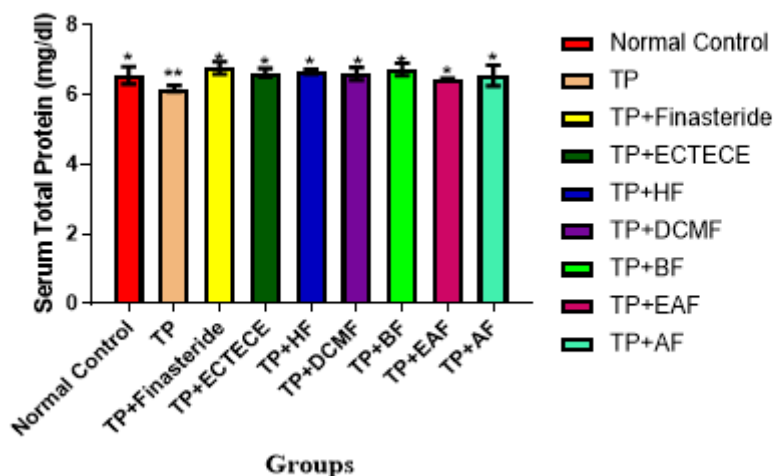
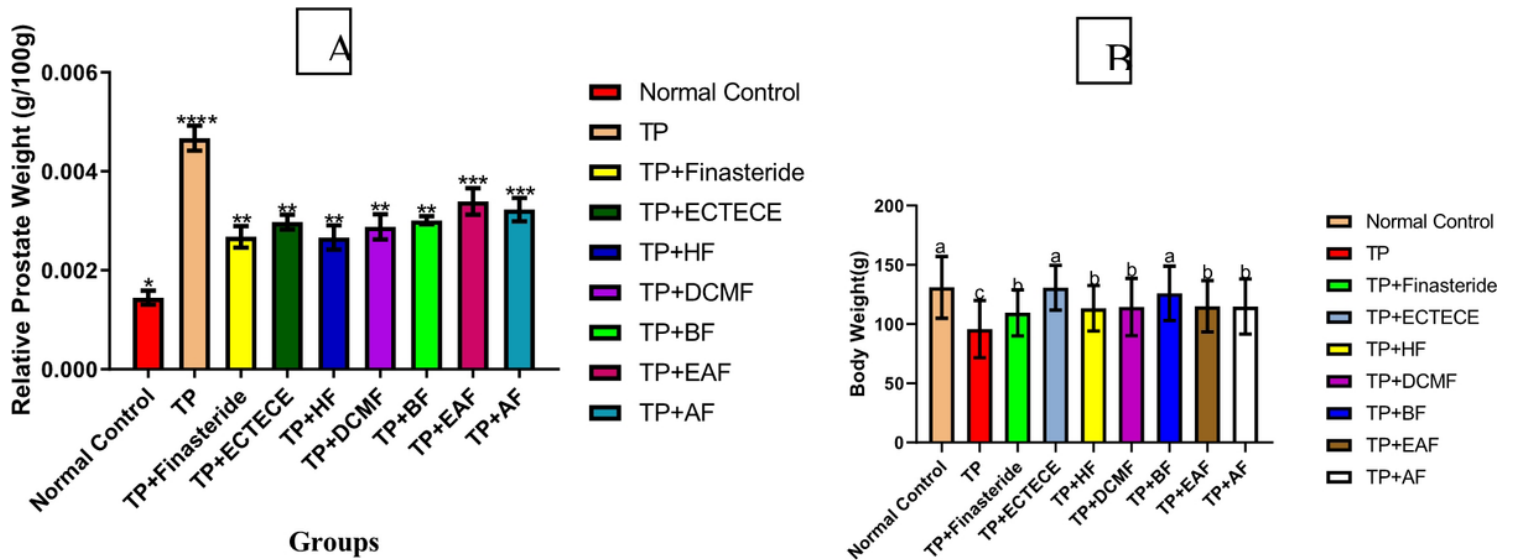


Figure 1

Effect of ethanol crude Tuber extract of *C. esculenta* and Fractions on Serum Total Protein concentration in Testosterone propionate induced benign prostate hyperplastic Rats. Data are shown as mean  $\pm$  S.D (n=5). Mean values with the different signs are significantly different at  $P < 0.05$ . Testosterone propionate (TP), Ethanol crude Tuber extract of *C. esculenta* (ECTECE), Hexane fraction(HF), Dichloromethane fraction ( DCMF), Butanone fraction(BF), Ethyl acetate fraction(EAF) and Aqueous Fraction (AF)



**Figure 2**

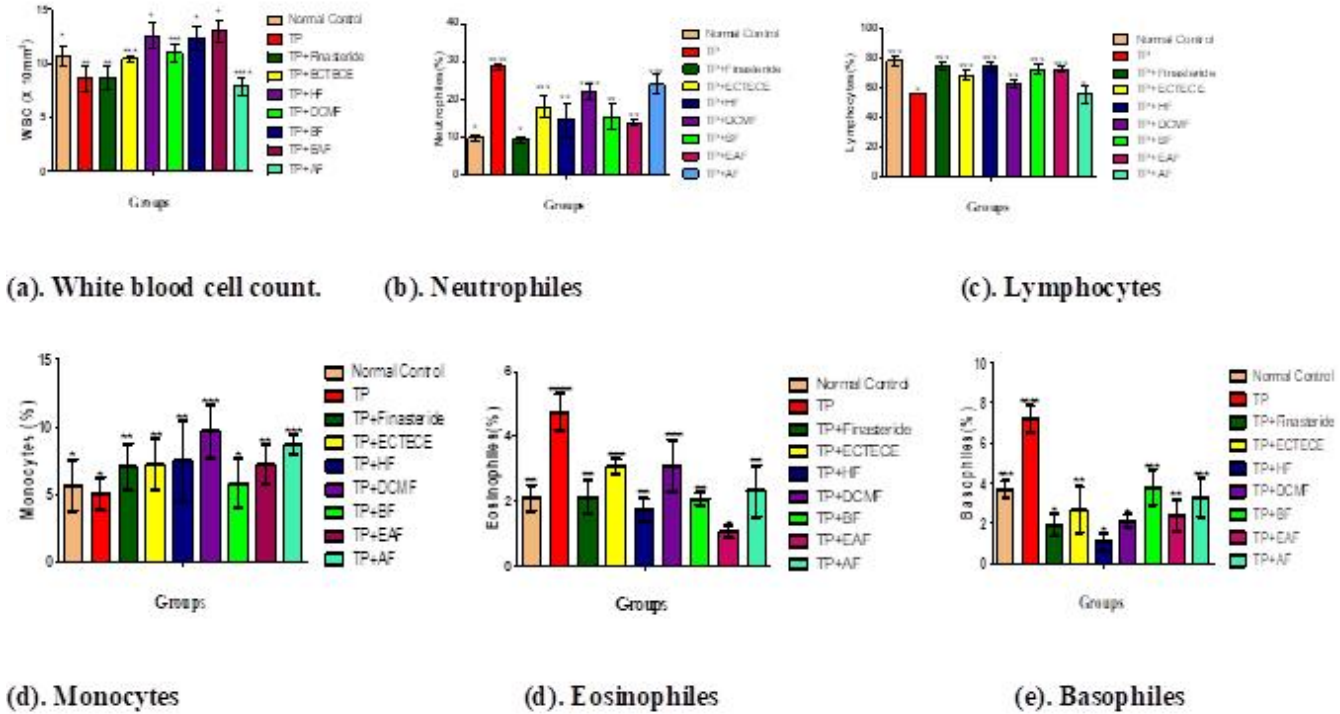
Effect of ethanol crude Tuber extract of *C. esculenta* and Fractions on Relative Prostrate Weight in Testosterone propionate induced benign prostate hyperplastic Rats. Data are shown as mean  $\pm$  S.D (n=5). Mean values with the different signs are significantly different at  $P < 0.05$ . Testosterone propionate (TP), Ethanol crude Tuber extract of *C. esculenta* (ECTECE), Hexane fraction (HF), Dichloromethane fraction (DCMF), Butanone fraction (BF), Ethyl acetate fraction (EAF) and Aqueous Fraction (AF)

**Figure 3**

(a-d): Effect of ethanol crude Tuber extract and Fractions of *C. esculenta* on Relative Organs weights in Testosterone propionate induced benign prostate hyperplastic Rats. Data are shown as mean  $\pm$  S.D (n=5). Mean values with the different signs are significantly different at  $P < 0.05$ . Testosterone propionate (TP), Ethanol crude Tuber extract of *C. esculenta* (ECTECE), Hexane fraction (HF), Dichloromethane fraction (DCMF), Butanone fraction (BF), Ethyl acetate fraction (EAF) and Aqueous Fraction (AF)

**Figure 4**

**(a-g):** Effect of ethanol crude Tuber extract of *C. esculenta* and Fractions on Haematological indices in Testosterone propionate induced benign prostate hyperplastic Rats. Data are shown as mean  $\pm$  S.D (n=5). Mean values with the different signs are significantly different at  $P < 0.05$ . Testosterone propionate (TP), Ethanol crude Tuber extract of *C. esculenta* (ECTECE), Hexane fraction (HF), Dichloromethane fraction (DCMF), Butanone fraction (BF), Ethyl acetate fraction (EAF) and Aqueous Fraction (AF)




**Figure 5**

**(a-f):** Effect of ethanol crude Tuber extract and Fractions of *Colocasia esculenta* on WBC level and differential counts in Testosterone propionate induced benign prostate hyperplastic Rats. Data are shown as mean  $\pm$  S.D (n=5). Mean values with the different signs are significantly different at  $P < 0.05$ . Testosterone propionate (TP), Ethanol crude Tuber extract of *Colocasia esculenta* (ECTECE), Hexane fraction(HF), Dichloromethane fraction ( DCMF), Butanone fraction(BF), Ethyl acetate fraction(EAF) and Aqueous Fraction (AF).



## Figure 6

Haematoxylin and Eosin stain on histological sections of prostate gland. I. (NC) Normal control group (magnification, x200); II. (TP+ Finasteride) Positive control group (magnification, x200); III. TP + ECTECE (magnification, x200); iv. (BPH) Negative control group (magnification, x200). Blue arrows show the prostate glands with no proliferating prostate cells while the red arrows show proliferating prostate cell, BPH- Benign prostatic hyperplasia, ethanol crude tuber extract of *C. esculenta*



**Figure 7**

**(I-II).** Haematoxylin and Eosin stain on histological sections of the liver. (I) Normal control group (NC) (magnification, x200); (II) BPH group (magnification, x200); and (III) TP +ECTECE group (magnification, x200). BPH- Benign prostatic hyperplasia, ethanol crude tuber extract of *C.esculenta*



### Figure 8

(I-IV) showed no demonstrable hyperplasia, atrophy or hypertrophy of heart tissue in the normal control group (NC), neither was it demonstrated in the BPH group nor TP + Finasteride groups. The same was observed in TP + ECTECE group.

### Figure 9

**(I-IV).** Haematoxylin and Eosin stain on histological sections of kidney tissue. (I) Normal control (NC) group (magnification, x200); (II) BPH control group (magnification, x200); (III) TP + Finasteride (magnification, x200) and (IV) TP + ECTECE (magnification, x200). BPH- Benign prostatic hyperplasia, ethanol crude tuber extract of *C. esculenta*