ResearchGate

See discussions, stats, and author profiles for this publication at: https://www.researchgate.net/publication/226724012

The Parasites of the Gorillas in Bwindi Impenetrable National Park, Uganda

Chapter · January 2006

DOI: 10.1007/978-0-387-33505-6_10

CITATIONS
7

READS
277

4 authors:

Jessica M Rothman
City University of New York - Hunter College
171 PUBLICATIONS **4,506** CITATIONS

SEE PROFILE

Dwight Bowman
Cornell University
257 PUBLICATIONS **6,927** CITATIONS

SEE PROFILE

Gladys Kalema-Zikusoka
Royal Veterinary College
29 PUBLICATIONS **596** CITATIONS

SEE PROFILE

John Bosco Nkurunungi
Mbarara University of Science & Technology (MUST)
20 PUBLICATIONS **507** CITATIONS

SEE PROFILE

Some of the authors of this publication are also working on these related projects:

Project Kinship in Olive Baboons View project

Project Nutritional immunology in wild orangutans View project

All content following this page was uploaded by Jessica M Rothman on 20 December 2013.

The user has requested enhancement of the downloaded file.

CHAPTER TEN

The Parasites of the Gorillas in Bwindi Impenetrable National Park, Uganda

Jessica M. Rothman, Dwight D. Bowman, Gladys Kalema-Zikusoka, and John Bosco Nkurunungi

INTRODUCTION

Detecting disease threats to endangered species and their ecosystems plays a crucial role in the survival of a population (McCallum & Dobson, 1995). As human pressure increases around and within habitats that contain endangered species, so does the potential for disease transmission. Communities and wildlife managers must act proactively to discourage and prevent zoonotic disease transmission between humans and endangered wildlife.

Jessica M. Rothman • Department of Animal Science, Cornell University, Ithaca, NY 14853, USA **Dwight D. Bowman** • Department of Veterinary Microbiology & Immunology, College of Veterinary Medicine, Cornell University, Ithaca, NY 14853, USA **Gladys Kalema-Zikusoka** • Conservation Through Public Health, P.O. Box 4483, Kampala, Uganda **John Bosco Nkurunungi** • Department of Zoology, Makerere University, Kampala, Uganda.

Primates of Western Uganda, edited by Nicholas E. Newton-Fisher, Hugh Notman, James D. Paterson, and Vernon Reynolds. Springer, New York, 2006.

Highly endangered mountain gorillas (*Gorilla beringei*) are found in only two isolated populations: the Virunga Volcanoes located on the borders of Uganda, Rwanda, and the Democratic Republic of Congo, and Bwindi Impenetrable National Park (BINP) in southwestern Uganda. Both areas are surrounded by some of the most densely populated and intensively cultivated areas in Africa. Approximately 700 mountain gorillas remain; 320 live in BINP (McNeilage *et al.*, 2001). While mountain gorillas in the Virunga Volcanoes have been extensively studied for the past 35 years (Plumptre & Williamson, 2001; Stewart *et al.*, 2001), those in BINP have not been a focus of the scientific community until recently.

Approximately 20% of the mountain gorilla population in BINP is habituated to humans, for either tourism or research purposes. While strict health guidelines and preventative regulations for park staff, tourists, and researchers have been recommended and/or implemented specifically for mountain gorillas (Homsy, 1999; Mudakikwa *et al.*, 2001; J. M. Rothman, personal observation), they are sometimes not practiced and all recommendations have not been yet been implemented (Woodford *et al.*, 2002; J. Rothman, personal observation). A medical survey of the local human population revealed that there was a high prevalence of disease symptoms compatible with infectious diseases that could be potentially transferable to the gorillas, and, when local people enter the park, more than half do not bury their feces (Guerrera *et al.*, 2003). Bwindi gorillas were victims of *Sarcoptes scabies*, which was likely the result of contact with infected humans (Graczyk *et al.*, 2001a; Kalema-Zikusoka *et al.*, 2002). As a result of habituation for tourism and research, gorillas are less fearful of ranging near park boundaries and outside the park into surrounding villages. This familiarity with people is likely to bring the gorillas into shared habitats more often, with an increased chance of shared disease. In addition, because of civil unrest and political instability in the region, wildlife populations are at higher risk of disease transmission from military presence in parks and human traffic (Mudakikwa *et al.*, 1998; Hamilton *et al.*, 2000; Dudley *et al.*, 2002). As habitats are destroyed, the home ranges of different groups are likely to overlap, and may be intensively overused by gorillas, which may increase their frequency of contact with pathogens.

To mitigate the transmission of parasites from humans to gorillas, park-established rules must be strictly enforced and reviewed in a timely manner (Homsey, 1999). Communities surrounding the park should be recipients of conservation education and they should be monitored and treated

for infectious diseases. Occupational health programs should be implemented so that park staff, researchers (both foreign and local) are properly vaccinated and periodically screened for infectious diseases (Nutter & Whittier, 2000). Often overlooked, military and security personnel should be included in conservation plans (Ngabirano, 2005). In addition, local farmers should be educated on practices that would reduce overlapping ranges of wildlife and livestock, and take preventative measures against livestock disease. Crop raiding by gorillas should be discouraged. A population and habitat viability assessment report considered disease to be one of the most devastating threats to the gorilla population (Werikhe *et al.*, 1997), and therefore conservation plans should seriously address, implement, and stringently enforce their policies.

A critical need of disease control management is screening, which is helpful in recognizing and understanding the history of outbreaks (Woodroffe, 1999). The collection and analysis of fecal samples is a less invasive method of understanding aspects of the health of the gorilla population (Ashford *et al.*, 1996) compared to other diagnostic techniques that involve physical contact and/or the administration of anesthesia. Fecal samples can provide information about some parasites, bacterial populations, genetics, nutrition, and stress levels. Regular monitoring and observations of habituated groups by trained park staff already visiting the groups for other purposes can assist in identifying sick animals with clinical symptoms. Opportunistic collection of wild gorilla fecal samples provides important baseline data to compare with habituated groups, and allows for monitoring of rarely encountered gorillas. Protocols for the standardized collection and analysis of fecal samples have been developed by the Mountain Gorilla Veterinary Project (Cooper *et al.*, 1996; Cranfield *et al.*, 2002;). In addition, trained pathologists should necropsy dead animals (Lowenstine, 1990). The Uganda Wildlife Authority (UWA) has done an excellent job of providing veterinary care to the mountain gorillas, and, through their veterinary program, they employ an on-site veterinarian for BINP. The Mountain Gorilla Veterinary Program (MGVP) assists in monitoring the health of the mountain gorillas along with UWA (Cranfield *et al.*, 2002). MGVP's primary objective is to provide emergency care to injured and seriously sick gorillas, and monitor the health of mountain gorilla groups, but they have also contributed greatly to disease surveillance and monitoring, identifying parasites present in the Bwindi gorilla population and carrying out necropsies (Cranfield *et al.*, 2002). Conservation Through Public Health (CTPH) is a newly developed NGO that promotes the

health of the local people, their animals, and wildlife. Several other NGOs work together with UWA to monitor the health of the gorillas.

This system-based review focuses on the parasites of the mountain gorillas in Bwindi Impenetrable National Park (BINP). These parasites have been identified at least once in different groups of Bwindi gorillas, thus it is expected that they may be encountered again. Anyone involved in the management of the gorillas, especially those monitoring the gorillas on a regular basis, will find information on the history, morphology, method of transmission, life cycle, and clinical signs of each parasite recorded in the Bwindi population. It is hoped that this review will be a useful reference for those who are interested in learning more about the parasites of Bwindi gorillas.

SURVEY OF PARASITES

The Stomach

Hyostrongylus kigeziensis *[Nematoda, Order: Strongylida, Family: Trichostrongylidea]*

Hyostrongylus kigeziensis was described from specimens collected from a necropsied Bwindi mountain gorilla (Durrette-Desset *et al.*, 1992), and was later described by Sleeman *et al.* (2000) in the Virunga population. Other hosts of this genus of nematodes include the Ethiopian Leporidae, Suidae, and a few Bovidae.

Living worms are often bright red in color. Females are about 1 cm long, males slightly shorter. The male has a distinct copulatory bursa and short stout spicules. *Hyostrongylus* can be differentiated from the *Paralibyostrongylus kalinae*, because the latter has large medial cuticular ridges at the level of the vulva.

At necropsy, the worms may be found on the mucosa of the stomach or in small, ulcerated areas on the mucosal surface. The eggs in the feces are typical strongylid eggs that are about 70–75 μm in length (Figure 1).

The mountain gorilla is the only known host of this species of *Hyostrongylus*. The life cycle of *Hyostrongylus kigeziensis* has not been described but it is expected to be similar to the life cycle of a swine parasite, *H. rubidus*. The life cycle is direct, and from eggs in the feces, first-stage larvae hatch. These feed on soil, grow, and molt to become nonfeeding third-stage larvae that are about

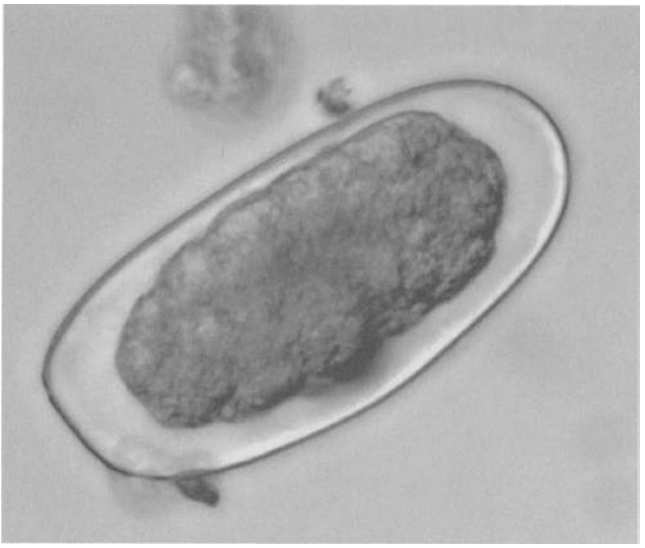

Figure 1. Typical strongylid egg found in the feces of the Bwindi gorilla population.

0.7 mm long and retain the second-stage larval cutical as a protective sheath. Nonfeeding third-stage larvae produced by the second molt are about 0.7 mm long and retain the second-stage larval cuticle as a protective sheath (Alicata, 1935). The gorillas are infected by the ingestion of larval contaminated foodstuffs. After ingestion, all development occurs in the stomach mucosa. Eggs appear in the feces about 3 weeks after infection. It is expected that the adult worms might induce a chronic catarrhal gastritis, leading to the formation of ulcers, as occurs in infected swine (Anderson, 2000).

Paralibyostrongylus kalinae *[Nematoda, Order: Strongylida, Family: Trichostrongylidae]*

This species was named after conservation biologist Jan Kalina, who with her husband Tom Butynski, facilitated the creation of the Bwindi Impenetrable National Park, and discovered this as a new species along with *Hyostrongylus kigeziensis* in the Bwindi population (Durette-Desset *et al.*, 1992).

The living adults are often bright red. There is a large dorsal esophageal tooth present. Females are about 1 cm long, males slightly shorter. The male has a distinct copulatory bursa, and short stout spicules. *Paralibyostrongylus kalina*, unlike *Hyostrongylus kigeziensis*, has large medial ridges at the level of

the vulva. The worms are found in the stomach at necropsy. The eggs are typical strongylid eggs (Figure 1), and are very similar to those of *Hyostrongylus.*

On the basis of the life cycle of the related species *P. hebrenicutus*, the host is probably infected through the skin, and the larvae reach the stomach within 2 days. If larvae are ingested through contaminated food or soil, they reach the stomach within 1 day. Larvae localize within the stomach mucosa. Eggs appear in the feces about a month after infection (Cassone *et al.*, 1992).

Small Intestine

Trichostrongylus *sp. [Nematoda, Order: Strongylida, Family: Trichostrongloidea]*

Gorillas are probably not the normal host of these parasites. However, without more careful descriptions, it is not possible to identify the actual host, which is likely a ruminant or a lagomorph.

Trichostrongylus sp. are small, brownish worms that are difficult to discern at necropsy without special care to examine the mucosal scrapings of the small intestine. The eggs in feces are typical of other strongylid nematodes, and may be confused with other parasitic nematodes common in the mountain gorilla. To identify eggs as being those of *Trichostrongylus*, it is necessary to culture the eggs and to examine hatched, developed third-stage larvae. The sheath extending beyond the tip of the tail is shorter than that of most other trichostrongylid parasites (Durette-Desset, 1974).

The life cycle of *Trichostrongylus* in gorillas is not known, but many experimental studies have been conducted in other animals, particularly ruminants and lagomorphs (Audebert *et al.*, 2003; see summaries in Levine, 1980; Anderson, 2000). The host becomes infected by ingesting the infective third-stage larvae. The eggs passed in the feces hatch and develop to first-stage larvae in the feces, where they feed on microorganisms. They develop to the second stage in a few days and then to the third-stage, ensheathed, infective larva. When larvae are consumed, they develop in the small intestine, and adults inhabit the anterior part of the small intestine.

There have been no clinical signs of disease associated with *Trichostrongylus* sp. reported from gorillas; however, the disease manifestations associated with trichostrongylosis is diarrhea that may sometimes be quite severe. In humans

infected with *Trichostrongylus*, slight abdominal discomfort is occasionally reported, but usually patients are asymptomatic (Boreham *et al.*, 1995).

Ascaris lumbricoides *[Nematoda, Order: Ascaridida, Family: Ascarididae]*

Ascaris lumbricoides is one of the most common parasites of people around the world and lives in an estimated 1.4 billion people (Crompton, 1999). In 1995, *A. lumbricoides* eggs were found in four fecal samples of Bwindi mountain gorillas (Kalema, 1995). In 1990, a study of the feces of people living around Bwindi forest revealed high loads of *Ascaris*, but there was no evidence of *Ascaris* in gorilla populations (Ashford *et al.*, 1990).

A. lumbricoides is a large cream-colored worm that will reach lengths of up to 30 cm or greater. The worms have three large lips on the anterior end. The tail is relatively short and comes to a rather abruptly pointed tip. The male tail curls ventrally and has no bursa.

A. lumbricoides worms would be difficult to confuse with any of the other parasites that might be found in the small intestine of gorillas at necropsy. There are no reports of necropsied gorillas infected with *Ascaris* sp.

A. lumbricoides eggs are ovoid and about 60 μm long. The eggs have a thick shell and a rough outer coat typically stained by bile to a golden brown color. When passed in feces, the eggs usually contain a single undivided cell. Humans and other primates are the hosts of *A. lumbricoides*, and become infected by ingesting infected soil or foodstuffs. The eggs persist in the soil for long periods and can remain infectious in soil for years. It takes about 2 weeks under optimal conditions for eggs to become infectious through the embryonation of the larvae to the infective stage. After ingestion of an infective egg, larvae hatch. The hatched larvae migrate into the intestinal wall and travel through the portal circulation to the liver, heart, and, through the pulmonary vessels, to their destination, the interalveolar tissues of the lung. The larvae then make their way up the respiratory escalator and are then swallowed. The remainder of the development takes place in the lumen of the small intestine. The prepatent period is about 2 months, and the worms live about 1 year. The females produce prodigious amounts of eggs, having been shown to produce about 200,000 eggs per day (Khera, 2000).

There are no clinical signs reported in mountain gorillas. In humans, light infections usually produce little in the way of signs or symptoms. Heavy infections can cause intestinal obstruction and related signs. It has been shown in people that *A. lumbricoides* infections do have some effect on the nutrition of their human hosts (see review by Crompton & Nesheim, 2002).

Strongyloides fulleborni *[Nematoda, Order: Rhabditida, Family: Strongyloididae]*

Strongyloides fulleborni eggs have been reported in the feces of mountain gorillas in both Bwindi and the Virungas (Ashford *et al.*, 1990, 1996; Kalema, 1995a,b; Mudakikwa *et al.*, 1998; Nkurunungi, 1999; Sleeman *et al.*, 2000).

The parasitic parthenogenetic female is about 3.6–4.6 mm long. Like other *Strongyloides* sp., the female is slender and has an esophagus that is very long: one-fourth to one-third of the total body length. The ovary of *S. fulleborni*, like other species that produce eggs rather than larvae in the feces, spirals around the intestine. The eggs are clear, contain a larva, and measure 50–60 μm by 25–35 μm. It is easy to miss the transparent eggs in fecal samples. If the feces sit for any length of time at room temperature, the larvae are likely to hatch. The larvae of *Strongyloides* can be identified by their possession of a short rhabditiform esophagus with a distinct corpus, isthmus, and bulbus, and a genital primordium that is quite large, being longer than the body is wide (Premvati, 1958).

These worms will be overlooked at necropsy unless techniques are used that are designed specifically for their collection. It is best to use a small portion of fresh bowel (proximal small intestine) and suspend it with weights in a graduated cylinder of saline at 37°C overnight. The small worms will migrate out of the tissue and drop to the bottom of the cylinder. The next morning, the intestine can be removed from the cylinder, and the sediment examined for the presence of the small *Strongyloides.*

S. fulleborni is much more common in nonhuman primates than in humans even where the ranges overlap; it is believed that typically nonhuman primates are the major host of this parasite. The most common mode of infection is penetration of the skin by infective third-stage larvae. In people of the Democratic Republic of Congo, 26 of 76 infants less than 200 days of age were infected with this parasite (Brown & Girardeau, 1977). Examination of milk from nursing mothers revealed three *Strongyloides* larvae in one 2-ml sample of milk from a

nursing mother 2 weeks postpartum (Brown & Girardeau, 1977). It is expected that *Strongyloides fulleborni* would also be transmitted in nonhuman primate milk.

The infective larvae that develop in soil are 575–640 μm long and penetrate the skin. When larvae penetrate the skin, they enter the bloodstream and are carried to the lungs. From the lungs, the larvae make their way to the intestinal tract by entering the respiratory openings, being coughed up, and swallowed. It takes 9 days before eggs are passed in the feces. Larvae that penetrate the skin may also enter into muscle and other parts of the body where they are capable of persisting as larvae for extended periods. These larvae form the reservoir of larvae that cause transmammary transmission, which accounts for infection in newborn animals (Premvati, 1958).

The clinical sign of most significance in humans is the "swollen belly" syndrome that has been reported in neonate humans in New Guinea (Ashford *et al.*, 1992). It appears that the infection is well tolerated by adult humans. In the case of primates, there appear to be no reports dealing with the presentation of disease in infected animals.

Anoplocephala gorillae *[Cestoda, Order: Cyclophyllidea, Family: Anoplocephalidae]*

Nybelin (1924) described *Anoplocephala gorillae* from a mountain gorilla inhabiting Mount Sabinio, Kivu Volcano (Virunga Region). Ashford *et al.* (1990) found that Bwindi gorillas had an 85% prevalence of these cestodes in the populations sampled. This finding was confirmed through fecal examination of Bwindi gorilla groups in later surveys (Kalema, 1995a,b; Nkurunungi, 1999). Gorillas in the Virunga region were infected as well, and that prevalence between age–sex classes differed, with infants containing the lowest prevalence (57%) compared with adults (77–100%) (Sleeman *et al.*, 2000). In a study in 1992–1993, Nkurunungi (1999) found that all Bwindi gorillas sampled were infected with *A. gorillae*, with the exception of an infant.

Anoplocephala gorillae are relatively large cestodes with widely segmented thick bodies having a scolex with large muscular suckers and no rostellum. The tapeworms that have been described are about 10 cm long and about 1.5 cm wide (Nybelin, 1924).

At necropsy, large cream-colored worms will be found in the small intestine. Fossey (1983) recovered these worms from the large intestine in one necropsied

Figure 2. Anoplocephalid egg found in the feces of the Bwindi gorilla population.

Virunga mountain gorilla, and from the small intestine in another. Six of eight Virunga mountain gorillas were found to harbor this parasite (Fossey, 1983).

In sedimentations or direct smears, the eggs of anoplocephalid tapeworms appear rather dark, with a clear central area containing the hexacanth embryo (Figure 2). The shape tends to be that of an irregular spheroid. In sugar flotations, the eggs appear clearer, but the hexacanth embryo will be more evident.

The gorilla is probably infected by the accidental ingestion of infected orabatid mites present in vegetation or soil. In *A. perfoliata*—a related parasite that uses the horse as a final host—soil-dwelling oribatid mites are the intermediate hosts. The mite ingests the egg passed in the feces, and a larval tapeworm matures and grows within the body cavity of the mite. The horse is infected by the accidental ingestion of the infected oribatid mite. All development takes place within the lumen of the horse's intestinal tract (Denegri *et al.*, 1998). It is expected that the life cycle of *A. gorillae* would be similar.

Mudakikwa *et al.* (2001) attributed small-intestinal cestodiasis to *Anoplocephala* in six of eight mountain gorillas. Most Anoplocephalidae are relatively harmless. *A. perfoliata* is associated with ulceration and inflammation of the intestinal wall (Beroza *et al.*, 1983). There are no clinical symptoms described, and on the basis of related species, no significant pathology would be expected.

Giardia lamblia *[Protozoan, Order: Diplomonadida, Family: Hexamitidae]*

Giardia lamblia is a very common parasite and the cause for a reemerging infectious disease (Thompson, 2000). Hastings *et al.* (1992) first described *Giardia* in the feces of necropsied Virunga gorillas. Nizeyi *et al.* (1999) found *Giardia* in two fecal samples, with an overall prevalence in the population of 2% in nonhabituated Bwindi gorillas. The prevalence of *Giardia* in cattle living outside park boundaries in Bwindi can reach 35%, and may be a significant means of transmission to the gorillas (Nizeyi *et al.*, 2002a). People living in communities around the park could also be a source of *Giardia*, and although infection levels of humans living near gorilla habitat were generally low (5%), they should still be considered a potential source of transmission (Graczyk *et al.*, 2002a).

Giardia exists as both a trophozoite and a cyst. The trophozoite of *Giardia* is a 12–15-μm bilaterally symmetrical pear-shaped flagellate. There are two nuclei with central karyosomes, two axonemes, two blepharoplasts, two parabasal bodies, and four pairs of flagella. An ovoid sucking disc occupies approximately three-fourths of the ventral surface. The cyst is ellipsoidal, 9–12-μm, and contains two to four nuclei, with several of the structures of the trophozoite. This flagellate inhabits the small intestine (duodenum and upper jejunum), and at times the bile duct and gall bladder (Meyer, 1994).

At necropsy, fecal samples can be assessed for the presence of trophozoites and cysts.

Trophozoites may be detected in direct smears of diarrheal feces. Cysts may be found through fecal flotation in zinc sulfate.

Humans and other primates, domesticated pets, and livestock are all hosts of *Giardia*. It is probable that mountain gorillas are infected by ingesting contaminated food or water, or through accidental contact with infected feces of man and/or other gorillas. *Giardia* has a direct life cycle (Meyer, 1994). After the infective cyst is ingested, *Giardia* excysts and trophozoites attach to the epithelial cells of the small intestine by the use of its sucking disc. Trophozoites probably feed by absorbing nutrients through their surface and multiply by longitudinal binary fission. Encystation occurs as trophozoites move into the colon. Recently formed cysts have two nuclei, but the trophozoite will divide so that the mature cyst contains two trophozoites. Cysts are the infective stage passed in the feces. The prepatent period ranges from 6 to 15 days, and infections can last months

to years. *Giardia lamblia* is the only flagellated parasitic protozoa found in the small intestine, all others are found in the cecum and colon.

There are no published reports of clinical signs of giardiasis in wild or captive gorillas. Clinical signs in infected humans include diarrhea, malabsorption syndrome, nausea, flatulence, and weight loss. Nizeyi *et al.* (1999) report that the stool of gorillas harboring *Giardia* was normal (i.e., containing no blood or mucus).

Encephalitozoon intestinalis *[Protozoan, Order: Pleostphoridida, Family: Encephalitozoon]*

This intracelluar, protozoan parasite recently rectassified as fungi (Thomorat *et al.*, 2004), was found at 3% prevalence in fecal samples of the human-habituated groups of gorillas in BINP (Graczyk *et al.*, 2002b). It was also found in the human population living around BINP at a prevalence of 3% (Graczyk *et al.*, 2002b). *Encephalitozoon intestinalis* infects a wide range of mammals.

Microsporidia are obligate, intracellular, single-celled, spore-producing parasites that are about 1.2 × 2.0 μm in size (Wasson & Peper, 2000; Weiss, 2001). Diagnosis is through the identification of spores in infected fecal material, biopsy of infected area, and sometimes through the identification of spores in urine, bile, or nasal fluids. PCR and FISH can be used to detect the preserved spores in the biopsied tissues and fluids.

E. intestinalis is transmitted through the ingestion of spores and infects the enterocytes, macrophages, fibroblasts, and endothelial cells. The life cycle is direct. Ingested spores extrude a polar filament that injects parasite DNA into a host cell. Within the host cell, the sporoplasm divides to yield meronts. These mature and yield infective spores. The host cell then bursts and the infective spores are released (Wasson & Peper, 2000). Gorillas infected with *E. intestinalis* had stool containing blood and mucus (Graczyk *et al.*, 2002b). In humans, *E. intestinalis* is most prevalent in immunocompromised hosts and causes ulcerative enteritis and cystitis, colitis, and hepatitis.

Cryptosporidium parvum *[Protozoan, Order: Eucoccidiorida, Family: Cryptosporidiidae]*

Cryptosporidium is a minute coccidian parasite with a large distribution. There are more than 20 species described from fish, birds, mammals, and reptiles.

Nizeyi *et al.* (1999) were the first to describe the presence of *Cryptosporidium* oocysts in the feces of wild gorillas. Using immunofluorescence staining, 11 of 100 Bwindi gorilla fecal samples were positive for cysts (Nizeyi *et al.*, 1999). Molecular analysis revealed that these samples contained *Cryptosporidium parvum*, which can be transmitted zoonotically between mammals and humans (Graczyk *et al.*, 2001b). The species *C. hominis* is restricted to humans, and it is not known if it occurs in gorillas. Captive populations of lowland gorillas are also known to rarely harbor *Cryptosporidium* (Gomez *et al.*, 1996). Cattle and people living outside park boundaries in Bwindi may be a reservoir of *Cryptosporidium* (Nizeyi *et al.*, 2002a,b).

The oocysts when passed in the feces contain four sporozoites and a residual body. The wall of oocysts are red with acid-fast staining. The oocysts reported from gorillas are 4.3–5.6 μm in diameter (Nizeyi *et al.*, 1999). Various fluorescent antibody test kits have been developed for the detection of this parasite in human feces, and there are also ELISA kits that can be used to detect free antigen in the fecal matter of infected hosts. More recently, PCR techniques have been used to distinguish species of oocysts present in fecal matter using extracted DNA or RNA.

In histological sections at necropsy, the life-cycle stages of *C. parvum* are found just under the surface of enterocytes. These very small stages can be observed with routine histopathology of the intestinal mucosa, although the probability of sectioning the appropriate area within the intestine is small.

Cryptosporidium is transmitted through direct fecal–oral transmission of the oocyst stage. Excystation occurs in the upper gastrointestinal tract, and the developmental stages are found in the brush border of the mucosal epithelium of the intestine. Sporozoites develop into trophozoites, which undergo schizogony to produce Type I schizonts (containing eight merozoites each) and then Type II schizonts (containing four merozoites each). The Type II schizonts initiate a gametogenous cycle, which, by forming micro and macro gametocytes, form mature gametes. Fusion of the gametes occurs, and oocysts are produced.

Nyzeyi *et al.* (1999) report that 3 of 11 mountain gorillas found to be infected with *Cryptosporidium* had blood and mucus in their stool; however, neither sign is typically associated with cryptosporidiosis. In humans, acute, watery diarrhea is often a clinical sign of cryptosporidiasis and, in some cases, nausea, vomiting, abdominal cramps, and fever. In infants and young children, dehydration from

diarrhea and vomiting can have a fatal outcome. Fortunately, there have been no reports of infant gorillas dying of symptoms associated with cryptosporidiosis.

Large Intestine

Murshidia devians *[Nematoda, Order: Strongylida, Family: Strongylidae]*

Campana-Rouget (1959) described *Murshidia devians* from a lowland gorilla in the Republic of Congo and suggested that the parasite was an accidental parasite of the gorilla owing to its close affinity with parasites of elephants and its recovery from ectopic sites. Hastings *et al.* (1992) report finding *M. devians* in the large intestine of a mountain gorilla at necropsy. Ashford *et al.* (1996) identified the worms during the necropsy of a mountain gorilla in the Bwindi forest.

Members of the genus have a large buccal capsule with an external leaf crown that has about 80 elements and no teeth at the base of the buccal capsule (Campana-Rouget, 1959). The worms are about 20 mm long. The vulva of the female is located just anterior to the anus. The bursa of the male has a well-developed dorsal lobe (Lane, 1914).

The adults are typically found free within the lumen of the large intestine (Hastings *et al.*, 1992). Fossey (1983) reported finding the worms in the small intestine of a necropsied older female mountain gorilla. Campana-Rouget (1959) found worms in ectopic sites. Thus, it is possible that worms may be found in sites other than the intestine.

Eggs of the typical strongylid type may be detected in the feces (Figure 1); the eggs are 60 by 30 μm. When third-stage larvae are cultured in feces, they are found to have a long sheath that extends beyond the tip of the tail (Bhat & Manikam, 1998).

There is no information on the life cycle of any *Murshidia* sp. Like other members of the subfamily Cyathostominae, *Murshidia* probably has a direct life cycle. Eggs passed in the feces hatch on the ground to release the first-stage larvae, which feeds on bacteria. The first-stage larvae molt to second-stage larvae that also feed on bacteria. The second stage molts to the third-stage larvae that are ensheathed. The development in the final host has not been studied. The finding of the adults of *Murshidia* in ectopic sites in the gorilla would indicate that there might be some form of extraintestinal development associated with the development of these worms in their normal hosts.

Oesophagostomum stephanostomum *[Nematoda, Order: Strongylida, Family: Chabertiidae]*

This species was first described from gorillas in 1904 (Stossich, 1904). The worms were preserved in the zoology museum of Cambridge University, with the designation "from large intestines of gorilla," without any indication as to where the host originated. Rousselot and Pellissier (1952) reported on the presence of *Oesophagostomum stephanostomum* in western lowland gorillas from the Republic of Congo. Specimens of this genus were later found at necropsy of Virunga gorillas (Hastings *et al.,* 1992), in Bwindi gorillas (Ashford *et al.*, 1996) and in larval cultures (Sleeman *et al.*, 2000). Surveys found eggs identified as *Oesophagostomum* in the feces of gorillas from the Bwindi population (Kalema, 1995a,b; Ashford *et al.*, 1990, 1996).

Adult females are 18–30 mm in length, and males 18–24 mm. The worm has a relatively small buccal cavity compared to other members of strongyloidea and a marked transverse cervical groove at the excretory pore. The stoma has both external and internal leaf crowns, with the external crown having 30–38 petals. There are two to three times as many petals on the internal leaf crown. The base of the buccal capsule contains six rather large chitinous plates. The male has a prominent bursa and two rather long spicules. The vulva of the female is near the anus and the vagina connects to the kidney shaped ovejector (Stossich, 1904).

Adults live in the lumen of the large intestine. Larvae form nodules in the intestinal wall. These nodules are small raised areas about 1 mm in diameter in the small and large intestine. The lesions can grow into small abscesses, and eventually the entire intestine may be inflamed and edematous. Nodules may reach 4–5 mm in diameter, and contain eosinophils and leukocytes. There can be a significant number of nodules at necropsy; 40 nodules were found in one of nine gorillas in the Congo (Rousselot & Pellissier, 1952). Eggs are 60–80 μm by 40–55 μm and are typical strongylid eggs (Figure 1). When cultured to the infective stage, the third-stage larva is about 1 mm long, has 16–24 triangular intestinal cells, and a sheath that extends 150 μm beyond the tip of the larva.

The hosts of *O. stephanostomum* are gorillas, chimpanzees, and humans (reported from Uganda, Senegal, and, surprisingly, Brazil) (Chabaud & Lariviere, 1958). There is no information on the life cycle of *O. stephanostomum*. The life cycle is probably similar to related species such as *O. bifurcum*, another species found in Old World primates. After larvae are ingested, it takes approximately 3 months until eggs appear in the feces (Eberhard *et al.*, 2001). The molt from

third to fourth stage occurs sometime before 19–22 days after infection. Some young adult worms were still present in nodules within the bowel wall after almost a year from the time of infection. Animals can shed eggs for almost a year.

Disease was first associated with gorillas captured for zoological collections in Gabon and the Republic of Congo (Rousselot & Pellissier, 1952). The gorillas died within a few months of capture following ill health. Fecal examinations revealed the eggs of strongylid nematodes, and necropsies later revealed that the gorillas were infected with both hookworms and had nodular disease due to oesophagostomins. The clinical signs manifested as anorexia and lack of grooming, with an unkempt appearance. There was mucoid diarrhea similar to amebic dysentery in humans. The gorillas remained lying or sitting, holding their heads with both hands in an attitude of desperation. In free-ranging mountain gorillas, nodules of oesophagostomiasis and a fatty degeneration of the liver were first described from gorillas captured for European zoos (van den Berghe *et al.*, 1964), and the authors attributed two of the captured gorillas' death to *O. stephanostomum*. More recently, nodules have been observed at necropsy by the Mountain Gorilla Veterinary Center (cited in Sleeman *et al.*, 2000; Mudakikwa *et al.*, 2001), and Hastings *et al.* (1988) speculate that feces containing blood and mucus may indicate infection caused by *Oesophagostomum*.

Probstmayria gorillae *[Nematoda, Order: Ascardida, Family: Atractidae]*

In 1955, Kreis described *Probstmayria gorillae* based on specimens collected from a gorilla that died in a zoo in Basel, Switzerland. Specimens belonging to the genus *Probstmayria* have been described from mountain gorillas in both the Virunga region (Fossey, 1983; Sleeman *et al.*, 2000) and in groups of gorillas in Bwindi Impenetrable National Park (Ashford *et al.*, 1990; Rothman *et al.*, 2002). Ashford *et al.* (1990) found that gorillas had a 100% prevalence of *Probstmayria*, while Rothman and others (2002) found a 13% prevalence in a single group sampled over 7 weeks. Specimens collected from the feces of lowland gorillas in Gabon have been described as two species distinct from *Probstmayria gorillae*; these two species were named *Probstmayria goodallae* and *Probstmayria gabonensis* (van Waerebeke *et al.*, 1988).

Probstmayria gorillae are small worms with an esophagus that has a large valved bulb at the base and a vestibule between the stoma and the beginning

of the muscular esophagus proper. The female gives birth to large larvae that are almost one-third her total length.

At necropsy, larvae and adults are found in the lumen of the cecum and colon. The adults are not large (females are only about 2 mm long). Fecal examination will reveal both adults and larvae. The birth of highly precocious larvae with no requirement for an intermediate host means that very large populations can develop within an infected animal.

The hosts of *Probstmayria* sp. include gorillas, chimpanzees, pigs, horses, and tapirs. The life cycle is direct; the host ingests the third-stage larvae, usually through infected foodstuffs or by fecal–oral contamination. Transmission is probably assisted by the fact that larvae can remain alive in feces for 4 or 5 days. This species has not been found to be pathogenic.

Trichuris trichiura *[Nematoda, Order: Enoplida, Family: Trichuridae]*

Ashford *et al.* (1990) reported that the game guards at Bwindi Impenetrable National Park were infected with *Trichuris trichiura* and that it did not appear to be infecting the gorillas at that time. However, a later report (Kalema, 1995a,b) found that the gorillas in the same area where Ashford *et al.* (1990) conducted their study were infected. In Nkurunungi's study (1999), *Trichuris* was found in the Bwindi population. Nkurunungi claimed that the eggs found were morphologically dissimilar to *T. trichuria*. Sleeman *et al.* (2000) found 1 of 74 fecal samples from the Virunga population of mountain gorillas positive for *Trichuris* eggs. They were of the opinion that it was the same as *T. trichiura* found in man, and were concerned that it was a case of transfer from humans to habituated gorillas (Sleeman *et al.*, 2000).

Trichuris adult parasites live with their anterior ends threaded through the mucosa of the large bowel. The worms are about 2–3 cm long and have a very thin anterior end that encloses the stichosome esophagus characteristic of this group of worms.

At necropsy, the worms will be found as small cream-colored worms attached to the wall of the cecum. Uncommonly, worms in humans are found in the wall of the appendix and in the colon, probably when present in large numbers. The exact location of the worms in gorillas at necropsy has not been described.

The eggs of *T. trichiura* are characteristic and would be difficult to confuse with other eggs passed in the feces of gorillas. The eggs contain a single cell

when passed in the feces and are brown and lemon shaped, with polar plugs; the eggs are about 50 μm long.

The hosts of *T. trichiura* are humans and other primates. *T. trichiura* is a common parasite of people, and there is a good chance that it could move into the gorilla population if the gorillas were to become infected and the soils were of an appropriate type to support the transmission of this parasite.

Transmission is by the ingestion of eggs containing an infective-stage larva. Eggs can persist in the soil for many years. Eggs passed in the feces enter the soil environment, where they embryonate and become infectious. Infection is obtained by the ingestion of an egg either in soil or soil-contaminated foodstuffs. Once ingested, the eggs hatch within the large intestine, and the larvae penetrate the wall, where they develop. The adult worms will lay eggs 2–3 months after eggs are ingested. Worms probably live somewhere between 1 and 4 years. Clinical signs have not been reported in gorillas. Clinical symptoms in people include anemia, growth stunting, and, in massive infections, prolapse of the rectum.

Skin

Pthirus gorillae *[Arthropod, Order: Anoplura, Family: Phthiriidae]*

This sucking louse was first identified from specimens of mountain gorillas collected during a game hunting trip in 1927 to the Democratic Republic of Congo (Ewing, 1927). Kim and Emerson (1968) further described and illustrated the morphology of these sucking lice found by Ewing, and from captive eastern lowland gorillas collected from the Democratic Republic of Congo. Dian Fossey found this louse during necropsies of mountain gorillas in the Virunga region (Fossey, 1983). A female gorilla in BINP necropsied shortly after her death was found to have several *Pthirus gorillae* in her stomach; she was probably engaged in social or allo-grooming shortly before her death (Ashford *et al.*, 1996).

This species resembles the human pubic louse (*Pthirus pubis*), but unlike *P. pubis*, it has large eyes that are placed on large lateral protuberances. It has not more than 20 small abdominal setae. *Pthirus gorillae* is about 2.20 mm long, and it is a short and broad sucking louse with sprawling legs (Kim & Emerson, 1968).

The life cycle of *P. pubis* is direct, and in humans is usually transmitted through sexual contact. It would be expected that gorillas would transmit *Pthirus gorillae* to each other by social grooming, shared bedding, and through sexual contact. *P. pubis* spends its entire life on the widely spaced hairs of its

host, and the cycle from egg to egg takes about a month. *P. pubis* causes pruritus and papular dermititis.

Sarcoptes scabiei *[Arthropod, Order: Acariformes, Family: Sarcoptidae]*

The genus *Sarcoptes* causes a condition described as scabies in humans and non-human primates, and sarcoptic mange in domestic and wild animals. *Sarcoptes scabiei* was first described in mountain gorillas in Bwindi Impenetrable National Park in 1996 (Kalema-Zikusoka *et al.*, 2002) and then again in a later outbreak (Graczyk *et al.*, 2001a). To date, this condition has not been observed in the Virunga mountain gorillas. This parasite was later reported in the chimpanzees (*Pan troglodytes schweinfurthii*) of Gombe National Park (Pusey, 1998).

A tourist-habituated group of four gorillas developed varying degrees of pruritis, alopecia, and white scaly skin that appeared to be age- and size-related. The male infant gorilla had approximately 75% alopecia and was emaciated and making frequent crying sounds. The male juvenile gorilla had approximately 90% hair thinning, with alopecia and skin thickening. The adult female gorilla and mother of the infant had alopecia, and was scratching frequently. The adult male silverback gorilla only showed signs of pruritis, with no clear visual signs of alopecia. In the immobilized juvenile male, skin scrapes and biopsies revealed mites typical of *S. scabiei* (Kalema-Zikusoka *et al.*, 2002). The infant died and necropsy revealed severe emaciation, with a body weight of 2.8 kg at the age of 8 months. The skin was thick and scaly, with crusts and alopecia on the neck, back, legs, chest, and arms. The only part of the body with hair was the head. The skin showed numerous mites and eggs. The skin biopsies revealed severe cutaneous acariasis associated with marked acanthosis, spongiosis, ballooning degeneration, and hyperkeratosis, with few signs of inflammation. The primary cause of death was scabies, with secondary pneumonia, dehydration, and inanition (Kalema-Zikusoka *et al.*, 2002). The rest of the group recovered with one dose of intramuscular Ivermectin, and could not be immobilized for a further dose.

The affected group occasionally ranged in people's gardens and ate banana plants. Three months prior to showing clinical signs, the group spent several days in gardens where people had rough skin due to scabies. The *S. scabiei* mite is ubiquitous, normally causing mild disease in the normal host, but can settle in temporary hosts and cause severe disease especially if the host is closely related (Ibrahim & Abu-Samra, 1985) and naive to the mites. In the case of the

mountain gorillas, the most likely source of the mites would be people. However, the possibility of the source of scabies coming from other animals sharing the Bwindi forest habitat cannot be ruled out. Stress may have contributed to the severity of scabies. This group was being visited by tourists. Cheetahs in Masai Mara, Kenya, under greater pressure from tourist visitation developed sarcoptic mange that was not observed in other cheetahs (Mwanzia, 1995). Four years later another scabies outbreak occurred in another group of gorillas, which was being habituated for tourism (Graczyk *et al.*, 2001a), causing morbidity, but no mortality. The group recovered with Ivermectin treatment. The Nkuringo group also spent time outside the park in people's gardens and public pathways. Further research revealed that the prevalence of scabies in the community surrounding this gorilla group is high, where 45.7% admitted to having had the disease and three (37.5%) of the eight people who agreed to have skin scrapes and were also showing clinical signs were positive for scabies (Nziza, 2003). In addition, the scabies mites in the skin scrapes from these people were found to be genetically similar to the mites found in the mountain gorillas (Ndizihiwe, unpublished data; Nziza, 2003). These findings suggest that the mountain gorilla scabies probably came from the surrounding local community.

S. scabiei mites are circular in shape and the females (330–600 μm by 250–400 μm) are slightly larger than the males (200–240 by 150–200 μm). Mellanby (1944) first described the life cycle of *S. scabiei* in man. *Sarcoptes* are burrowing mites, and the female mites lay 40–50 eggs in the tunnel they form in the epidermis. In 3–5 days, these eggs hatch into six-legged larvae; some of which develop into nymphs within the tunnels and eventually become sexually active males and females. The time from egg production to development of adult mites is an estimated 17 days. The adult female is then fertilized by the male, and extends the tunnel laying more eggs. These fertilized females are responsible for the main spread of infection together with the wandering larvae, nymphs, and fertilized young. The scabies mites are susceptible to dryness and cannot survive for more than a few days off their host. The burrowing mites suck lymph and feed on epidermal cells, causing marked irritation, leading to further itching and scratching. The inflammation causes exudation from the skin that coagulates to form crusts, excessive keratinization and proliferation of connective tissue, and resultant thickening and wrinkling of the skin. Pruritis appears after 2–6 weeks (Mellanby, 1944).

SUMMARY

Parasite surveys in Bwindi Impenetrable National Park have revealed that at least 16 parasites infect Bwindi gorillas, 10 helminths, 1 cestode, 3 protozoa, and 2 arthropods. Of these, there are 14 endoparasites and 2 ectoparasites. A summary comparing the parasites found in wild populations of the three subspecies of gorillas can be found in Table 1. Parasites found in captive gorillas were not included (not a complete list, but see Lane, 1923; Sandosham, 1950;

Table 1. The parasites of free-ranging gorillas

	Study population			
	Gorilla beringei[a] (Bwindi)	*Gorilla beringei beringei*[b] (Virunga)	*Gorilla beringei graueri*[c]	*Gorilla gorilla gorilla*[d]
Helminths				
Cestodes				
Anoplocephala gorillae	X	X	X	
Tapeworms (unidentified)				X
Nematodes				
Ascaris sp.				X
Ascaris lumbricoides	X			
Capillaria hepatica		X		
Chitwoodspirura wehri		X[e]		X
Gongylonema sp.				X[e]
Hyostrongylus sp.		X		
Hyostrongylus kigeziensis	X			
Impalaia sp.		X		
Loa loa sp.				X
Mansonella lopeensis				X
Mansonella perstans				X[e]
Murshidia devians	X			
Oesophagostomum sp.	X	X	X	
Oesophagostomum stephanostomum	X			
Paralibyostrongylus kalinae	X			
Probstymaria gabonensis				X
Probstymaria goodallae				X
Probstymaria gorillae	X	X		
Probstymaria sp.	X	X		
Strongyles	X	X	X	
Strongyloides fulleborni	X	X		X
Strongyloides sp.				X
Trichostrongylus sp.	X	X		
Trichuris trichuria	X	X		

(cont.)

Table 1. *(Continued)*

	Study population			
	Gorilla beringei[a] (Bwindi)	*Gorilla beringei beringei*[b] (Virunga)	*Gorilla beringei graueri*[c]	*Gorilla gorilla gorilla*[d]
Protozoa				
Balantidium coli			X	X
Chilomastix mesnili		X		
Cryptosporidium	X			
Encephalitozoon intestinalis	X			
Endolimax nana		X		
Entamoeba coli		X		
Entamoeba hartmanni		X		X
Entamoeba histolytica		X		X
Enteromonas hominis			X	
Giardia lamblia	X	X	X	
Iodamoeba buetscheli		X	X	X
Pentatrichomonas hominis				X[e]
Arthropods				
Pthirus gorillae	X	X		
Psoroptes sp.		X[e]		
Sarcoptes scabies	X			
Other				
Various ciliates (commensal)	X	X	X	X

[a] Ashford *et al.*, 1990, 1996; Durette-Desset *et al.*, 1992; Kalema, 1995a,b; Nizeyi *et al.*, 1999; Nkurunungi, 1999; Graczyk *et al.*, 2001a,b; Kalema-Zikusoka *et al.*, 2002; Rothman *et al.*, 2002.
[b] Nyeblin, 1924; Fossey, 1983; Redmond, 1983; Hastings *et al.*, 1992; Graczyk *et al.*, 1999; Mudakikwa *et al.*, 1999; Sleeman *et al.*, 2000.
[c] Eilenberger, 1998.
[d] Chabaud & Rousselot, 1956; Garin *et al.*, 1982; Goussard *et al.*, 1983; van Waerebeke *et al.*, 1988; Imai *et al.*, 1991; Bain *et al.*, 1995; Landsoud-Soukate *et al.*, 1995; Lilly *et al.*, 2002.
[e] Author was unable to make a definitive conclusion as to the diagnosis of the parasite.

Amberson & Schwarz, 1952; Fain, 1957; Rousselot & Pellissier, 1952; Chabaud & Rousselot, 1956; Yamashita, 1963; Noda & Yamada, 1964; van de Berghe *et al.*, 1964; Mortelmans *et al.*, 1970; Flynn, 1973; Paciepnik, 1976, Graber & Gervey, 1981; Grady *et al.*, 1982; Taere & Loomis, 1982; Rehmann *et al.*, 2003) since the animals were not under natural conditions. In captive environments, animals are limited to a confined space and are sometimes under increased stress, thereby facilitating the transmission of natural parasites and introduced parasites from other hosts that may be housed nearby. However, the importance of captive studies should not be overlooked; information from zoo and captive animals provides a resource base for which parasites are capable of infecting wild gorillas. We encourage the regular monitoring of all populations of *Gorilla*.